



Tenofovir-induced Leukocytoclastic Vasculitis

Said A. Al-Busafi^{1*}, Abdulatif Al-Suleimani², Aysha Al-Hamadani³ and Wasif Rasool¹

¹Department of Medicine, Division of Gastroenterology and Hepatology, College of Medicine and Health Sciences, Sultan Qaboos University, Muscat, Oman

²Internal Medicine Training Program, Oman Medical Specialty Board, Muscat, Oman

³Department of Pathology, College of Medicine and Health Sciences, Sultan Qaboos University Muscat, Oman

ARTICLE INFO

Article history:

Received: 26 September 2015

Accepted: 21 October 2016

Online:

DOI 10.5001/omj.2017.80

Keywords:

Hepatitis B; Tenofovir;
Leukocytoclastic Vasculitis.

ABSTRACT

Tenofovir, a nucleotide analog, is one of the first-line medications recommended for the treatment of active chronic hepatitis B virus infection (CHB) and as a primary prophylaxis to prevent hepatitis B reactivation in cases of immunosuppression. We report the first case of tenofovir-induced leukocytoclastic vasculitis (LCV). A 43-year-old obese woman, who was known to have inactive CHB, was diagnosed with chronic immune thrombocytopenic purpura (ITP). She was treated with corticosteroid therapy and was put on tenofovir to prevent hepatitis B virus reactivation. A month later, she developed a skin rash, described as non-blanchable well-defined erythematous to violaceous papules and targetoid patches in her lower extremities. A skin biopsy showed features of LCV. The rash resolved completely within few days after replacing tenofovir with entecavir.

Leukocytoclastic vasculitis (LCV), also called hypersensitivity vasculitis, is a type of small-vessel vasculitis.¹ It can present either as cutaneous lesions e.g. palpable purpura or systemically, most commonly affecting joints, gastrointestinal tract, and the kidneys.² Systemic involvement is generally associated with a more severe disease course while cutaneous manifestations is usually self-limited and has an excellent prognosis.³ LCV may be idiopathic (in approximately half of the cases), or secondary to medications, infections, collagen-vascular disorders, or malignancy.⁴

Here, we report a case of a patient who developed LCV almost one month after the use of tenofovir. To the best of our knowledge, this is the first report of tenofovir-induced LCV.

CASE REPORT

A 43-year-old morbidly obese woman was admitted to our institution with a history of hypothyroidism (on thyroxine replacement therapy), type 2 diabetes mellitus (on metformin and gliclazide), and inactive chronic hepatitis B infection (CHB).

In 2012, the patient presented with purpuric skin rash and was found to have isolated

thrombocytopenia with a persistently low platelet account of $< 100 \times 10^9/L$. She was evaluated by the hematology team and underwent an immunological work-up, bone marrow aspiration, and karyotyping, which led to the final diagnosis of idiopathic thrombocytopenic purpura (ITP). Immunosuppressive therapy with corticosteroid was considered. Her pre-treatment hepatitis B status showed CHB (positive hepatitis B surface antigen) with negative hepatitis B viral protein (HBeAg) and persistently low viral load of < 20 IU/mL. Her liver enzymes and function tests showed persistent mild elevation in liver enzymes (aspartate transaminase of 88 IU/L and alanine transaminase of 63 IU/L) with normal liver function, which was attributed to fatty liver disease. The patient was discharged on prednisolone and tenofovir.

Three weeks later, the patient presented to the hospital with a two-week history of painful skin rash, mainly involving lower extremities, associated with a fever of 38.3 °C. Review of the other systems was unremarkable. Examination of the lower extremities revealed non-blanchable, well-defined palpable erythematous to violaceous papules, and targetoid patches with a mild hemorrhagic necrotic center surrounded by a mild violaceous to brownish borders. The rest of the physical exam was otherwise normal.

*Corresponding author: saidalbusafi@gmail.com

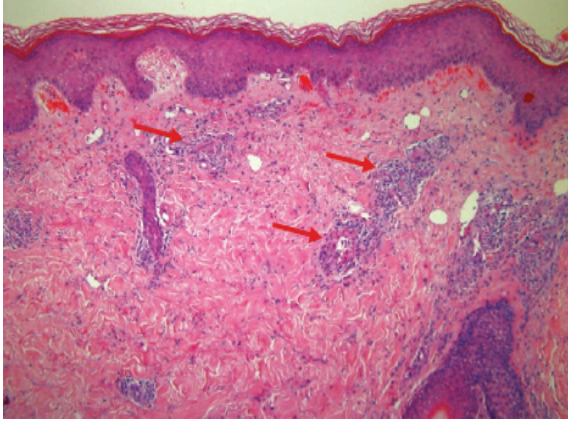


Figure 1: Hematoxylin and eosin stained skin biopsy showing epidermis and dermis with periadnexal and interstitial inflammatory cell infiltrate (red arrows), magnification = 5 ×.

The initial impression was minor erythema multiforme-drug induced versus LCV with superadded infection. The patient was admitted to the hospital and started on intravenous cefuroxime because of the possibility of cellulitis. Blood work-up showed mild neutrophilic leukocytosis, normal eosinophilia and platelets count. Her erythrocyte sedimentation rate (ESR) was high (60 mm/hr) and urinalysis and microscopy were within normal limits. She was seen and evaluated by the dermatologist and a skin biopsy was taken. The skin histopathology revealed findings suggestive of LCV [Figures 1 and 2]. Therefore, a diagnosis of LCV skin rash, which was most likely tenofovir-induced, was made. She was treated with a topical steroid cream. In addition,

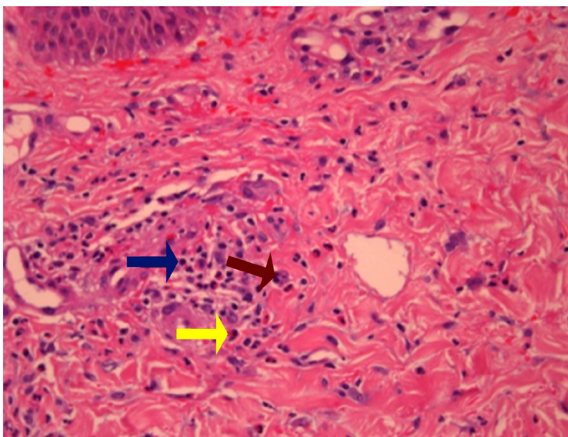


Figure 2: Hematoxylin and eosin stained skin biopsy showing mixed dermal infiltrate consisting predominantly of neutrophils (red arrow), admixed with eosinophils (yellow arrow), and lymphocytes (blue arrow), magnification = 40 ×.

tenofovir was stopped and replaced with entecavir. Two weeks later, the skin rash resolved completely.

DISCUSSION

Tenofovir is a well-tolerated, reverse transcriptase inhibitor which was approved as first-line therapy for CHB and human immunodeficiency virus (HIV) infections. Its primary drug-limiting toxicity is nephrotoxicity. Dermatologic adverse reactions are reported in 10–18% of cases including maculopapular, pustular, or vesiculobullous rash. It might also cause pruritus (16%), urticaria (5–18%), and diaphoresis (3%).⁵

There are several case reports of tenofovir-associated skin rash. The first case of tenofovir-induced photo-allergic reaction was reported in 2012. The rash appeared 48 hours after starting tenofovir, (proven by histopathology and photo-patch test) and disappeared after stopping the medication and treatment with an oral corticosteroid.⁵ In 2007, there was a report of nine HIV-infected patients with cutaneous reactions to tenofovir. The majority developed a maculopapular or vesicular rash, with a mean onset of 15 days. A rechallenge test was done for seven of the nine patients, and the rash characteristics were similar, including the site, in all patients.⁶ Our patient started to develop a rash almost one week after initiation of tenofovir therapy and histopathological findings suggested LCV rash, which makes tenofovir-related skin reaction more likely. After stopping tenofovir, the rash completely resolved, which further supports the diagnosis.

LCV is defined by the following five criteria proposed by the American College of Rheumatology⁷: 1) age > 16 at disease onset, 2) history of taking a medication at onset that may have been a precipitating factor, 3) the presence of palpable purpura, 4) the presence of maculopapular rash, and 5) a biopsy demonstrating granulocytes around an arteriole or a venule (LCV). The presence of three or more of these five criteria was associated with a sensitivity of 71.0% and a specificity of 83.9%.⁸ In the case of our patient, she met four out of the five criteria.

LCV is usually a benign syndrome which might be idiopathic (in approximately half of cases), or secondary to drugs, infections, or both.⁹ Many drugs have been reported as culprits, but penicillin, cephalosporin, sulfonamide, phenytoin,

and allopurinol have been most often implicated, while hepatitis B or C infection, HIV, and chronic infections (e.g. endocarditis) are some infections that might also cause this type of vasculitis.^{9,10}

Clinical manifestations of LCV include cutaneous lesions, systemic manifestations, and rarely internal organ involvement, which typically occur 7–10 days after exposure in most patients. Our patient developed the rash seven days after starting tenofovir. The skin findings were palpable purpura, petechiae, urticaria, and maculopapular rash, while systemic manifestations included fever, lymphadenopathy, and arthralgias. Internal organ involvement has also been reported, which includes proliferative glomerulonephritis, interstitial nephritis, and hepatitis. Other organs might be also involved but rarely.⁹

The diagnosis of this disorder depends on the typical clinical manifestations in relation to use of an offending drug or infection. Blood work-up typically shows high ESR with low serum complement levels. There might be evidence of hepatocellular injury of varying degree, hematuria, proteinuria, and cellular casts. The presence of cryoglobulins suggests mixed cryoglobulinemia as a diagnosis, often due to hepatitis C infection. Other investigations might be ordered according to the clinical suspicion (e.g., blood cultures and echocardiogram for endocarditis). Skin biopsy, as mentioned above, will show LCV. The major differential diagnoses are other systemic vasculitides and Henoch-Schonlein purpura.¹⁰

The treatment of hypersensitivity vasculitis includes discontinuation of the offending drug, which leads to resolution of the signs and symptoms within days to a few weeks. Treatment of underlying infection is important. Some patients might require non-steroidal anti-inflammatory drugs while colchicine, antihistamine, and dapsone (with pentoxifylline) may be helpful in severe or persistent cutaneous lesions, which are not due to infections.^{9,11}

Immunosuppressive therapy should be reserved for fulminant or progressive disease.

CONCLUSION

This is the first case report of tenofovir-induced LCV in a patient with CHB, which completely resolved two weeks later after the withdrawal of the drug.

Disclosure

The authors declared no conflicts of interest.

REFERENCES

- Lie JT. Nomenclature and classification of vasculitis: plus ça change, plus c'est la même chose. *Arthritis Rheum* 1994 Feb;37(2):181-186.
- Jennette JC, Falk RJ. Small-vessel vasculitis. *N Engl J Med* 1997 Nov;337(21):1512-1523
- Loricera J, Calvo-Rio V, Ortiz-Sanjuan F, Gonzalez-Lopez MA, Fernandez-Llaca H, Rueda-Gotor J, et al. The spectrum of paraneoplastic cutaneous vasculitis in a defined population: incidence and clinical features. *Medicine (Baltimore)* 2013 Nov;92(6):331-343.
- Tai YJ, Chong AH, Williams RA, Cumming S, Kelly RI. Retrospective analysis of adult patients with cutaneous leukocytoclastic vasculitis. *Australas J Dermatol* 2006 May;47(2):92-96.
- Verma R, Vasudevan B, Shankar S, Pragasam V, Suwal B, Venugopal R. First reported case of tenofovir-induced photoallergic reaction. *Indian J Pharmacol* 2012 Sep-Oct;44(5):651-653.
- Lockhart SM, Rathbun, RC, Stephens JR, Backer DL, Drevets DA, Greenfield RA, et al. Cutaneous reactions with tenofovir disoproxil fumarate: a report of nine cases. *ADIS: June* 2007;21(10):1370-1373.
- Calabrese LH, Michel BA, Bloch DA, Arend WP, Edworthy SM, Fauci AS, et al. The American College of Rheumatology 1990 criteria for the classification of hypersensitivity vasculitis. *Arthritis Rheum* 1990 Aug;33(8):1108-1113.
- Blanco R1, Martínez-Taboada VM, Rodríguez-Valverde V, García-Fuentes M; Cutaneous vasculitis in children and adults. Associated disease and etiologic factors in 303 patients. *Medicine (Baltimore)* 1998;77(6):403-418.
- Sais G, Vidaller A, Jucglà A, Gallardo F, Peyrí J. Colchicine in the treatment of cutaneous leukocytoclastic vasculitis. Results of a prospective, randomized controlled trial. *Arch Dermatol* 1995 Dec;131(12):1399-1402.
- Winkelmann RK, Wilson-Jones E, Smith NP, English JS, Greaves MW. Neutrophilic urticaria. *Acta Derm Venereol* 1988;68(2):129-133.
- Nürnberg W, Grabbe J, Czarnetzki BM. Urticarial vasculitis syndrome effectively treated with dapsone and pentoxifylline. *Acta Derm Venereol* 1995 Jan;75(1):54-56.