

Polyangiitis Overlap Syndrome: Polyarteritis Nodosa with Leukocytoclastic Vasculitis Associated with Left Ventricular Thrombus and Vocal Cord Palsy: A Case Report

Wahinuddin Sulaiman^{1,2*}, Henry Foong Boon Bee², Lim Wei Mei², Ng Theng Chun², Chin Yow Wen², Lee Bang Rom³, and Syed Ibrahim Jamalullail¹

¹Department of Medicine, Faculty of Medicine, Royal College of Medicine Universiti Kuala Lumpur, No 3, Jalan Greentown, 30450 Ipoh, Perak, Malaysia

²Department of Medicine, KPJ Ipoh Specialist Hospital, Ipoh, Jalan Raja DiHilir, Ipoh, Perak, Malaysia

³Pathology services, Prince Court Medical Centre, Kuala Lumpur, Federal Territory, Malaysia

Received: 19 July 2022

Accepted: 10 April 2023

*Corresponding author: wahinuddin@unikl.edu.my; nwahin@gmail.com

DOI 10.5001/omj.2024.25

Abstract

Polyangiitis overlap (PO) syndrome is a systemic vasculitis characterised by overlapping features of more than one well-defined vasculitic syndrome. We report a 38-year-old Malay man presenting with progressive dyspnoea and palpable purpura on his lower limbs. Diagnostic evaluation revealed a right sided segmental pulmonary consolidation with pleural effusion, systolic cardiac dysfunction with presence of an intra-cardiac thrombus and a left vocal cord palsy secondary to laryngeal mono-neuropathy. He tested negative for anti-neutrophil cytoplasmic antibodies (ANCA) and skin biopsy revealed leukocytoclastic vasculitis (LCV) with negative immunofluorescence studies. He fulfilled the American College of Rheumatology diagnostic criteria for polyarteritis nodosa (PAN) and idiopathic LCV. There are only 3 reports of PO syndrome with a combination of PAN overlapping with idiopathic LCV in the medical literature. To our knowledge, this is the first PO syndrome report with cardiopulmonary involvement and laryngeal mononeuropathy. This patient had an excellent response to remission induction utilizing high-dose corticosteroids and mycophenolate mofetil (MMF) and remains in remission on a steroid taper. It's vital to acknowledge overlapping vasculitic syndromes in clinical practise and their good response to immunosuppression. Treatment delays should be avoided to prevent vasculitic complications and irreversible organ dysfunction. MMF may be an acceptable alternative to cyclophosphamide as a remission induction agent for this condition.

Keywords: Polyangiitis Overlap Syndrome; Leukocytoclastic Vasculitis; Polyarteritis Nodosa; Pleural Effusion; Cardiac Thrombus; Vocal Cord Palsy; Corticosteroid; Mycophenolate.

Introduction

Polyangiitis overlap (PO) syndrome is a disease entity proposed by Leavitt and Fauci in 1986. (1) It is defined as a systemic vasculitis that cannot be classified into one of the well-defined vasculitic syndromes. We report a case of PO syndrome with a combination of polyarteritis nodosa (PAN) and idiopathic leukocytoclastic vasculitis (LCV) associated with cardiopulmonary involvement and vocal cord palsy. He was successfully treated with mycophenolate mofetil and corticosteroids without relapse of the vasculitis.

Case Report

A 38-year-old Malay man with no known comorbid, presented with a 3-month history of progressive dyspnea, intermittent fever, and bilateral lower limb rash eruption. His initial evaluation yielded a diagnosis of community acquired pneumonia. He was commenced on intravenous co-amoxiclav and azithromycin. Despite this, his condition progressively worsened with persistent pyrexia, tachypnoea, and tachycardia. This deterioration prompted further investigations to rule out deep seated infections, tuberculosis, and pulmonary embolism.

His laboratory findings revealed a prominent leucocytosis at $26.2 \times 10^3/\mu\text{L}$ (neutrophil 92.6%). His CRP and NT-proBNP were markedly elevated at 110.12 mg/L and 3203 pg/mL (<450 pg/mL) respectively. The rest of his laboratory work-up was unremarkable except for a low serum albumin (29 g/L).

His computed tomography (CT) pulmonary angiogram showed no evidence of pulmonary embolism but revealed a collapse-consolidation of the right peri-hilar region with a moderate pleural effusion [Figure 1]. His electrocardiogram revealed sinus tachycardia with poor R wave progression. Trans-thoracic echocardiography revealed grossly dilated left atrium and left ventricle with a left ventricular ejection fraction (LVEF) of 21% and presence of an LV thrombus. There were no valvular abnormalities [Figure 2]. A CT coronary angiography revealed a left anterior descending artery stenosis (50 -75%) without aneurysm formation.

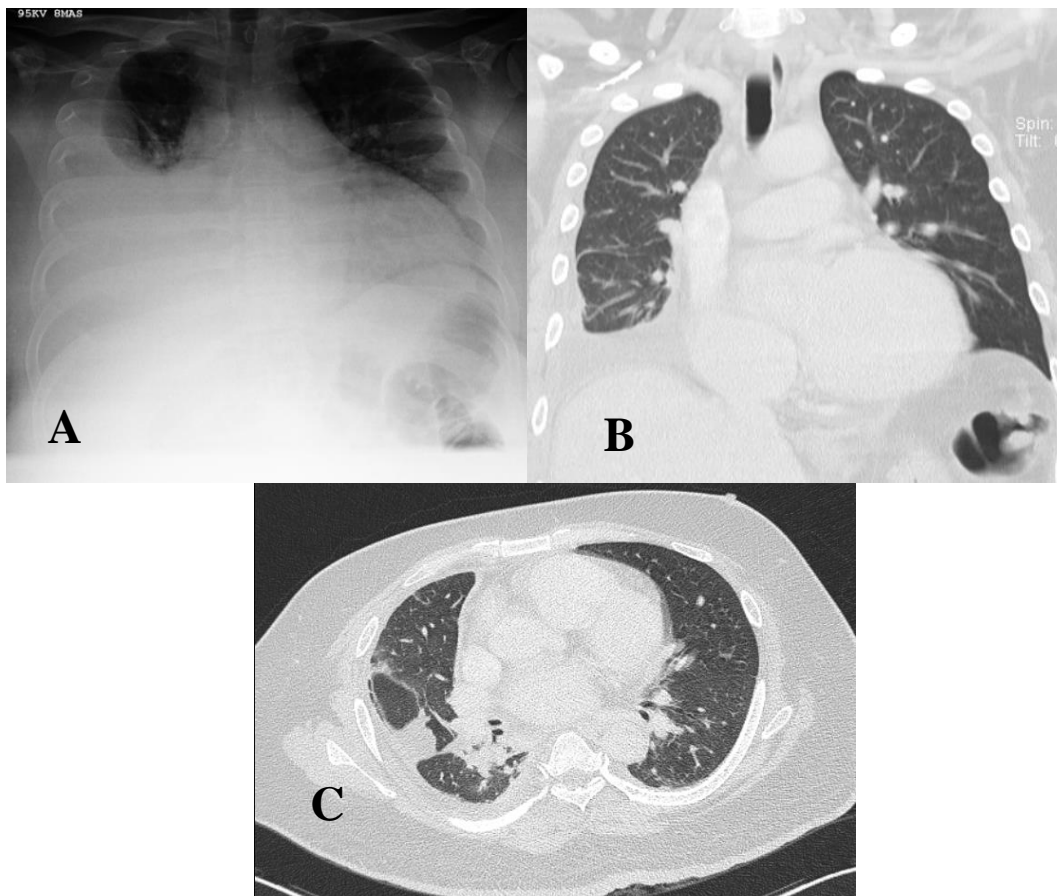


Figure 1: A) PA view chest radiograph showing right pleural effusion with enlarged cardiac silhouette. B) Coronal section CT scan thorax showing residual right pleural effusion with loculation in the right oblique and transverse fissures. C) Transverse section CT thorax showing collapse consolidation right perihilar region extending to the posterobasal and laterobasal segments.

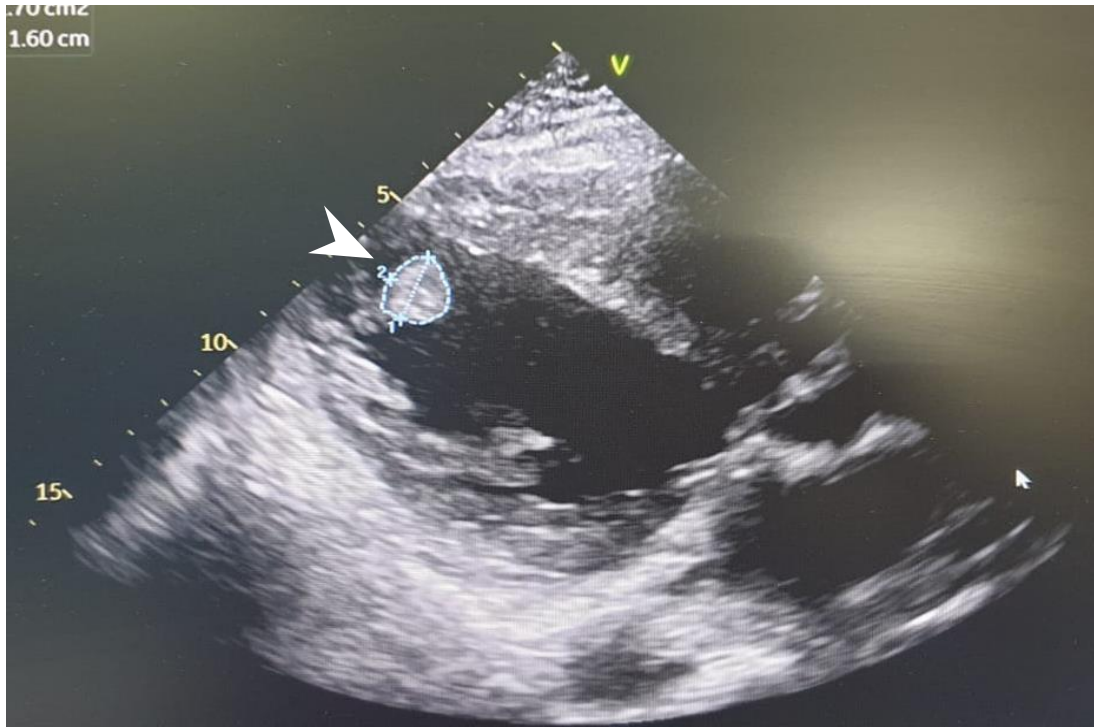


Figure 2: 2D echocardiography shows dilated LA and LV with apical LV thrombus (arrowhead)

Repeated blood cultures which were negative, and an extensive infective evaluation was unrevealing. The SARS CoV-2/COVID-19 RNA was not detected. Anti-hepatitis C virus (HCV) antibody, hepatitis B surface antigen (HBsAg), human immunodeficiency virus (HIV I/II antigen/antibodies) and Venereal Disease Research laboratory (VDRL) were non-reactive. GeneXpert™ for *Mycobacteria tuberculosis* (MTB Complex DNA and MTB/Rifampicin (RIF) Resistant Mutations *rpoB* gene) from blood was negative. Pleural fluid was exudative with a reactive leucocytosis (pleural fluid neutrophil and lymphocyte count of 1165/uL and 365/uL, In view of the negative infective screen in the setting of clinical deterioration, systemic vasculitis was strongly considered.

Upon re-evaluation, he denied chest pain, weight loss, anorexia, night sweats or other symptoms suggestive of an underlying connective tissue disease. He completed his COVID-19 vaccination 4 months prior to his initial symptoms. He denied taking over the counter or traditional medications.

Clinical examination revealed dysphonic speech and a temperature of 38.3°C. His blood pressure was 132/92 mmHg, pulse of 132 /minute (regular), respiratory rate 30/minute and oxygen saturation 96% (on room air). Generalised petechiae and palpable purpura with multiple necrotic ulcers were noted over both legs [Figure 3]. Neither peripheral lymphadenopathy nor uveitis were present. Apart from reduced air entry over the right lung base, the rest of his physical examination was unremarkable. Naso-endoscopy revealed a left vocal cord palsy without any lesions throughout the nasal passages, nasopharynx, and hypopharynx (suggestive of left recurrent laryngeal neuropathy).

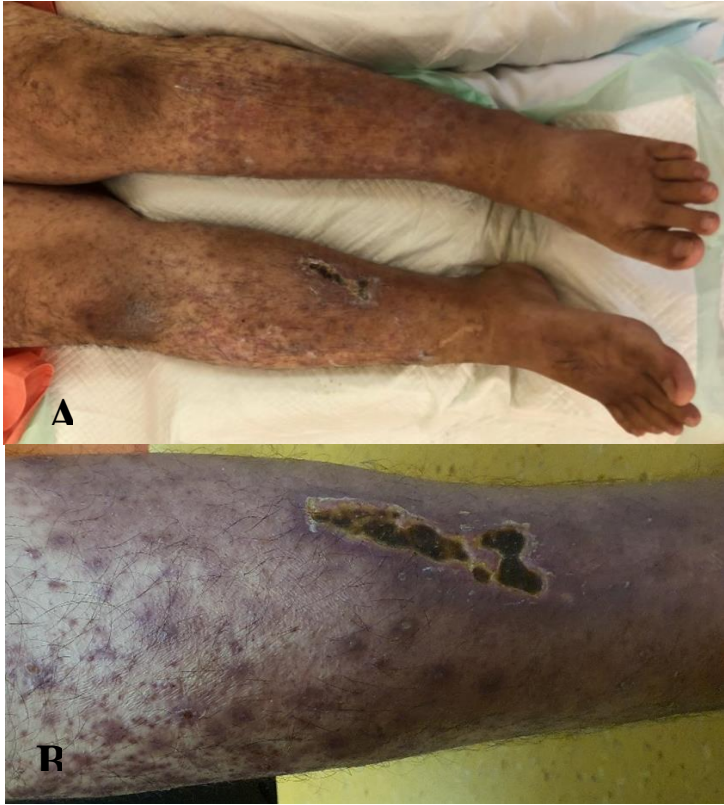

Figure 3: A) Extensive purpuric rashes with ulcer on both lower limbs. B) Close-up view.

His autoimmune (ANA, anti-dsDNA, p- and c-ANCA, C3 and C4, extractable nuclear antigens, myositis specific antibodies) and paraneoplastic screen was unrevealing. Unfortunately, he declined catheter angiography (to assess for visceral vasculitis). Biopsy from his eruptions revealed prominent fibrinoid necrosis in the superficial dermal vessels with neutrophilic infiltration and leukocytoclasia. The medium sized vessel of the subcutaneous fat were normal and immunofluorescence studies were negative [Figure 4]. These findings were consistent with cutaneous LCV.

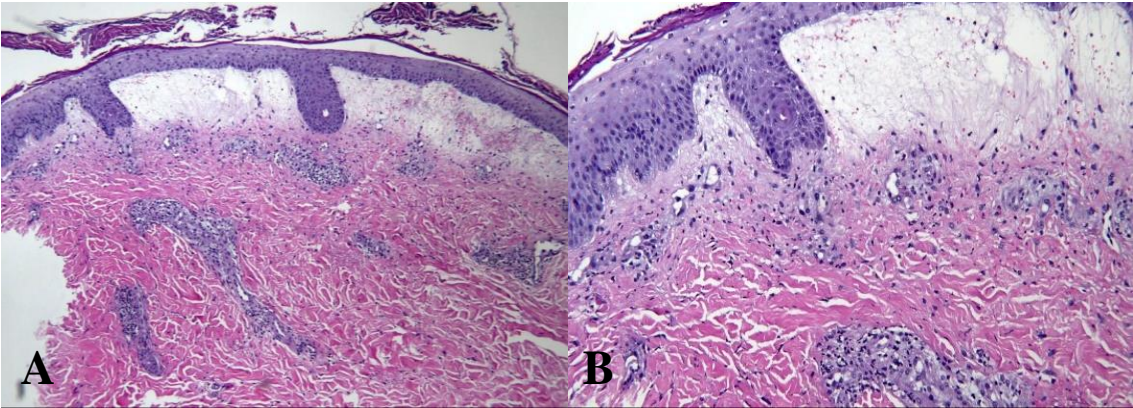


Figure 4: (A) HPE from skin biopsy with (B) magnification (40X) shows focal hyperkeratosis with subepidermal blisters filled with blood and neutrophils infiltration. There is necrosis with foci neutrophils and nuclear dusts of the blood vessels with prominent fibrinoid necrosis. Red blood cells extravasations and perivascular collections of mixed

inflammatory cells are present. The medium sized vessel at the subcutaneous fat shows no vasculitis. The immunofluorescence (IF) studies (IgG, IgA, IgM and C3) were negative.

This patient demonstrates clinical features of PAN (mononeuropathy, elevated diastolic blood pressure, occlusive coronary artery lesion) overlapping with cutaneous LCV. A diagnosis of PO syndrome was made. In view of his clinical deterioration, high dose corticosteroids with cyclophosphamide (CYC) infusion were planned. However, he declined induction with CYC.

He was induced with intravenous methylprednisolone 500mg daily for 3 days alongside mycophenolate mofetil (MMF) 500 mg twice daily. Rivaroxaban 15 mg twice daily was given for his intra-cardiac thrombus. He had marked symptomatic improvement with resolution of pyrexia, normalisation of physiological parameters and clearing of his cutaneous lesions after 3 to 4 days. He was subsequently discharged with oral prednisolone 40mg daily and MMF 500mg daily.

At two months post-discharge, he remained well with resolution of his dysphonia, pleural effusion, and cutaneous eruptions. His repeat hematological and biochemistry profile normalised. Given the good response to immunosuppression, he was put on a steroid taper and maintained on MMF 500mg daily. Unfortunately, he defaulted follow-up and treatment since then and developed decompensated heart failure and succumbed to the illness.

Discussion

This patient demonstrates clinical features fulfilling the diagnostic criteria for PAN (2). Although rare, bronchial artery vasculitis remains a recognized feature in PAN. This patient most likely had bronchial arteritis causing segmental pulmonary infarcts resulting to a collapse-consolidation and pleural effusion. His coronary artery occlusion resulted in permanent cardiac insufficiency due to the delayed presentation and diagnosis. The HPE findings of small vessel vasculitis preclude the diagnosis of classical PAN but will fall neatly within the diagnosis of PO syndrome.

Two cases of PO syndrome with a combination of PAN and idiopathic leukocytoclastic vasculitis were described in the medical literature, excluding in this patient (1, 3). This patient is unique as it presented with cardiopulmonary involvement and laryngeal neuropathy. Furthermore, both earlier cases utilized CYC with high dose corticosteroids for remission induction. Instead of CYC, this patient was given MMF with equally good response.

There are no existing treatment guidelines for this PO syndrome. Treatment described in the literature vary and is generally based on the known therapy for its overlapping components. However, the combination of CYC with high dose corticosteroids is the most commonly used (1, 4).

PAN is presumed to be an auto-reactive T cell mediated disease as it lacks associated autoantibodies. This lends support to the rationale of utilising CYC therapeutically. CYC is a DNA-alkylating agent that therapeutically leads to impaired T- cell division and apoptosis (5). MMF acts to deplete lymphocytic guanine nucleotides which subsequently exerts results comparable to CYC (6).

MMF for remission induction is known to be effective in PAN especially in pediatric population. Given its lesser toxicity profile compared to CYC, MMF may be an acceptable alternative as an induction agent.

Conclusion

PO syndrome is a systemic vasculitis not fulfilling the diagnostic criteria of well-defined vasculitic syndromes. Immunosuppression is effective in the treatment of this condition. Early treatment prevents subsequent vasculitic complications and permanent organ dysfunction. MMF may be an acceptable alternative to CYC in remission induction for PO syndrome with a combination of PAN and idiopathic LCV.

Conflict of interest

The authors declared no conflicts of interest.

References

1. Leavitt RY, Fauci AS. Polyangiitis overlap syndrome. Classification and prospective clinical experience. *Am J Med.* 1986;81(1):79-85. doi: 10.1016/0002-9343(86)90186-5.
2. Lightfoot RW Jr, Michel BA, Bloch DA, Hunder GG, Zvaifler NJ, McShane DJ, et al. The American College of Rheumatology 1990 criteria for the classification of polyarteritis nodosa. *Arthritis Rheum.* 1990;33(8):1088-93. doi: 10.1002/art.1780330805.
3. Pischel KD, Zvaifler NJ. Simultaneous occurrence of polyarteritis nodosa and leukocytoclastic vasculitis. *J Rheumatol.* 1984 Aug;11(4):542-4.
4. Shoda H, Kanda H, Tanaka R, Komagata Y, Misaki Y, Yamamoto K. Wegener's granulomatosis with eosinophilia. *Intern Med.* 2005 Jul;44(7):750-3. doi: 10.2169/internalmedicine.44.750.
5. Ahlmann M, Hempel G. The effect of cyclophosphamide on the immune system: implications for clinical cancer therapy. *Cancer Chemother Pharmacol.* 2016 Oct;78(4):661-71. doi: 10.1007/s00280-016-3152-1.
6. Ritter ML, Pirofski L. Mycophenolate mofetil: effects on cellular immune subsets, infectious complications, and antimicrobial activity. *Transpl Infect Dis.* 2009 Aug;11(4):290-7. doi: 10.1111/j.1399-3062.2009.00407.x.