

Unusual Cause of Diffuse Pleural Thickening (Malignant Pleural Mesothelioma Mimic): Undifferentiated Epithelioid Malignant Neoplasm

Jamal Al-Aghbari*, Amira Al Badi, Radiya Al Ajmi and Saif Al Mubaihsi

Consultant Pulmonologist, Sultan Qaboos University Hospital, Muscat

Received: 20 February 2023

Accepted: 10 April 2023

*Corresponding author: j-alaghbari83@hotmail.com, jamaln@squ.edu.om

DOI 10.5001/omj.2024.27

Abstract

Malignant pleural mesothelioma (MPM) is an aggressive malignancy associated with high mortality. Some malignancies may mimic MPM clinically and radiologically and can present a diagnostic challenge. In this report, we describe 57 years old-man with a clinical and radiological presentation in keeping with MPM however pleural biopsy showed undifferentiated epithelioid malignant neoplasm.

Keywords: Malignant Pleural Effusion (MPE); Malignancy; Pleural Biopsy.

Introduction

Malignant pleural mesothelioma (MPM) is an aggressive malignancy associated with high mortality. Some malignancies may mimic MPM clinically and radiologically and can present a diagnostic challenge. In this report, we describe 57 years old-man with a clinical and radiological presentation in keeping with MPM or its mimics however pleural histological and immunohistochemistry showed no clear evidence of a specific line of differentiation, making any determination of treatment very difficult. It was labeled as an undifferentiated epithelioid malignant neoplasm.

Case Report

We report a 57-year-old Egyptian man, a non-smoker who presented with three months history of left flank pain radiating to the left chest with a 10 kilograms weight loss. He had no other respiratory symptoms. There was no other significant past medical history, and no urinary complaints. He sought medical advice and was investigated and treated in the line of renal calculi; however computed tomography (CT) renal was normal. He is an electrical engineer, worked mainly as a researcher with no significant exposure to asbestos. Clinical examination reveals reduced breath sounds, reduced vocal resonance, and dullness over the left lower chest with no significant lymphadenopathy. Other systemic examination was unremarkable.

Initial laboratory investigations (electrolytes, liver function test, serum calcium and phosphate and urine analysis) were unremarkable apart from normocytic normochromic anemia with a hemoglobin of 10.4 g/dL. The chest X-ray showed blunting of the left costophrenic angle (Fig 1). High-resolution computed tomography (HRCT) of the chest was done and showed diffuse circumferential nodular pleural thickening encasing the left lung with mild to moderate pleural effusion and direct invasion of the posterior part of the 9th rib and left pericardium. (Fig 2A&2B). Further characterization by a positron emission tomography (PET) scan showed extensive fluorodeoxyglucose (FDG) uptake involving the left pleural thickening and entire left hemithorax extending into the adjacent mediastinum. There is bony erosion of this mass onto the posterior aspects of the left 9th rib and the transverse process of T9 vertebra. There are

multiple FDG avid retroperitoneal lymph nodes with maximum standard unit value (SUVmax) of 8.7. The left adrenal gland is nodular and demonstrates increased FDG uptake (SUVmax 4.6) (Fig 3A&3B).

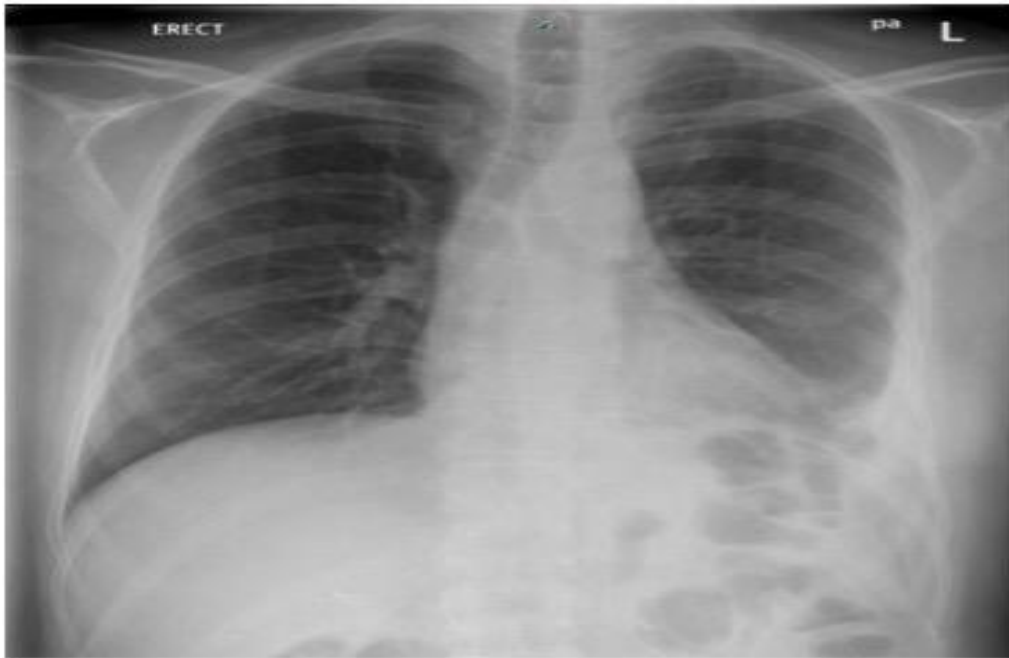

Fig1: Chest X-ray showed left costophrenic angle blunting

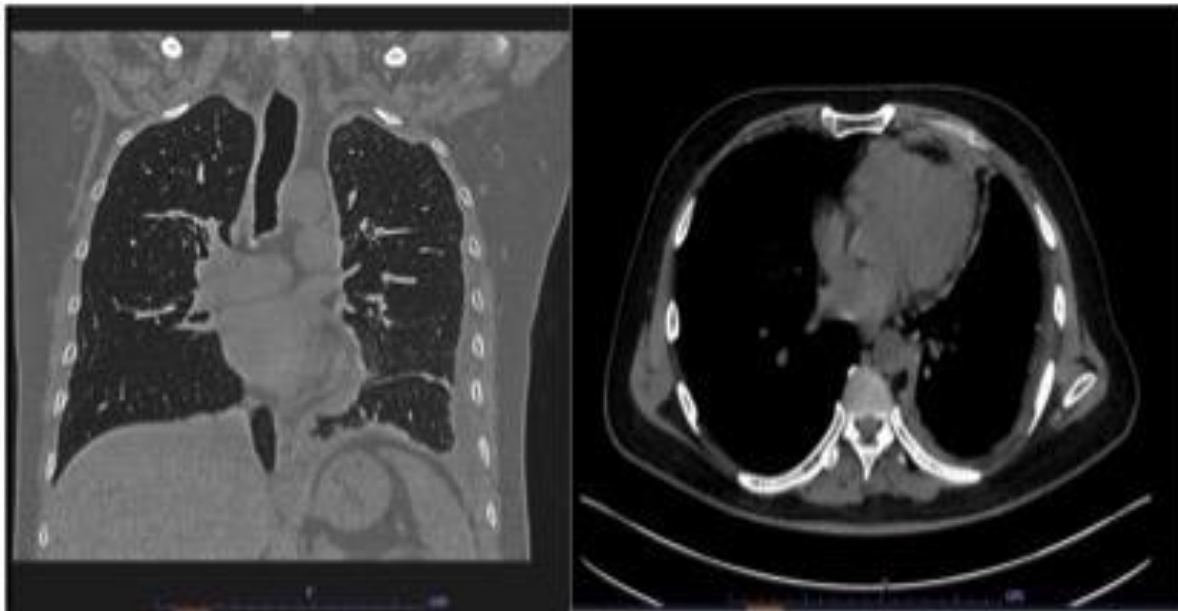


Fig 2A&2B: HRCT showed diffuse circumferential nodular pleural thickening encasing the left lung with mild to moderate pleural effusion and direct invasion of the left pericardium.

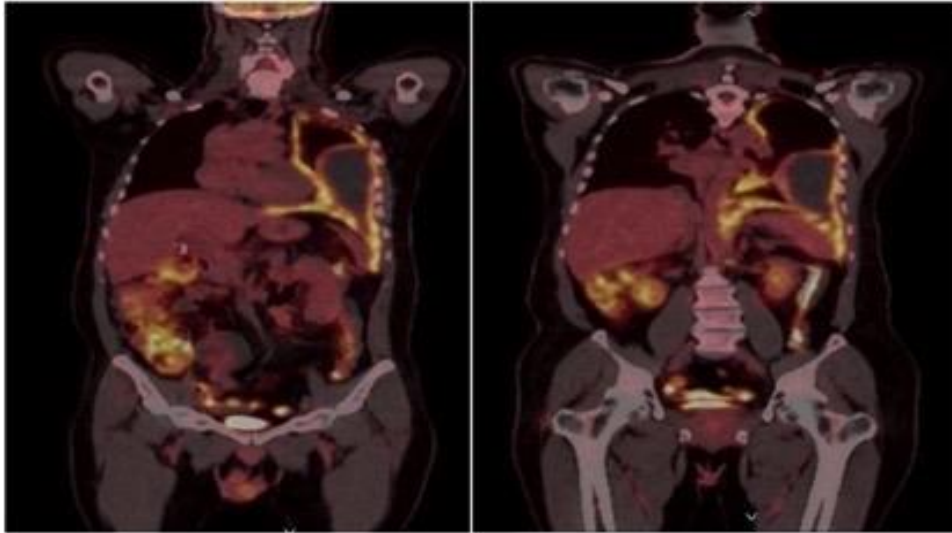


Fig 3A

Fig 3B

Fig 3A showed extensive circumferential nodular pleural thickening with significant FDG uptake involving the entire left hemithorax extending into the adjacent mediastinum. Fig 3B showed FDG avid retroperitoneal lymph nodes.

Video-assisted thoracoscopic surgery (VATS) was done, which revealed hemorrhagic pleural fluid, nodular thickening of the pleura with high vascularity and nodules over the left diaphragm. Multiple pleural biopsies were taken. Pleural fluid cytology revealed many lymphocytes, some neutrophils and eosinophils and occasional atypical cells. Tuberculosis GeneXpert was negative from the biopsy sample. No mycobacteria were isolated in the culture. Histopathology showed that the tissue is infiltrated by predominantly epithelioid cells with pale cytoplasm and large atypical vesicular nuclei with prominent nucleoli. These tumor cells are associated with a variable inflammatory infiltrate, including prominent histiocytes. Many mitotic figures, including atypical forms, are seen (Fig 4).

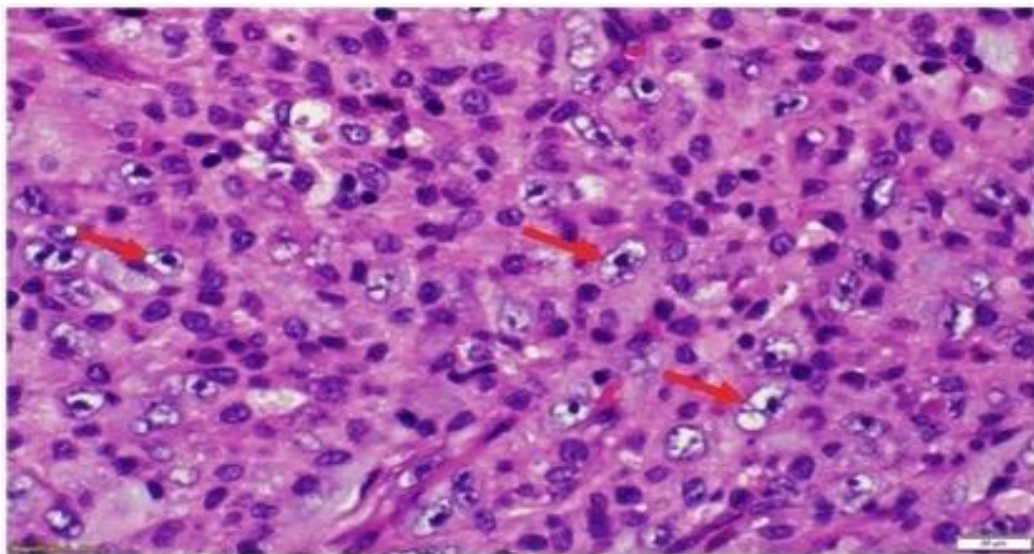


Fig 4: Hematoxylin and eosin (H&E) stain at x60 magnification. The specimen shows tissue which is infiltrated by predominantly epithelioid cells with pale cytoplasm and large atypical vesicular nuclei with prominent nucleoli (arrow). These tumor cells are associated with a variable inflammatory infiltrate including prominent histiocytes.

The atypical cells are negative for pan-keratin, CAM5.2, CK5/6, calretinin, WT1, D2-40, CK7, CK20, CDX2, TTF1, Napsin A, SMA, desmin, Melan A, inhibin, ALK1, CD34, Ber-Ep4, EMA, RCC, PSA, CD10, S100, LCA, CD3, CD20, CD15, CD30, PAX5, Mum1, CD21, CD23, BCL2, BCL6, CD138, EBER-ISH, CD1a, Myo-D1, Myogenin, PLAP, MPX and CD117, MDM2, CDK4, PU.1, CD163, claudin-4, CD34, SALL4, ERG and CD35. Staining for SMARCA4 is retained. Fluorescence in situ hybridization (FISH) for MDM2 gene amplification is negative. So, no clear evidence of a specific line of differentiation was concluded. Therefore, it was concluded as undifferentiated epithelioid malignant neoplasm.

Discussion

Malignant pleural mesothelioma (MPM) is an aggressive, rare malignancy associated with a low survival rate and high mortality. It has been recorded that MPM deaths are 9.9 per million per year among 59 countries based on world health organization (WHO) mortality data.⁽¹⁾ Typically, there is significant past exposure to asbestos decades before the presentation and radiological findings of diffuse unilateral pleural thickening, or mass or large pleural effusion, pleural plaque, or calcification.⁽²⁾ Histologically, all the mesothelial immunostains were negative in our patient (CK7, CK5/6, WT1, calretinin and D2-40). Therefore, malignant mesothelioma was not considered.

Some malignancies may mimic MPM clinically and radiologically, including sarcomas, pleural metastasis particularly lung adenocarcinoma,⁽³⁾ tuberculosis pleurisy^(4, 5) and diffuse large B-cell lymphoma.^(6, 7) Some of these tumors can directly invade the serosal membrane and behave like mesothelioma and present a diagnostic challenge.

Differentiating MPM from other malignant neoplasms or benign reactive processes is still an evolving subject. Generally, the presence of invasion features (e.g. invasion to the lung or ribs) makes the benign process very unlikely as it is in our patient.⁽⁸⁾ Sarcomatoid carcinoma involving the pleura is an extremely rare malignancy and tends to be very aggressive with rapid invasion. There are few case reports of pulmonary sarcomatoid carcinoma mimicking MPM; however all reports showed that histopathological examination of the biopsy showed positive stains for CK-7, AE1/AE3, and vimentin.⁽⁹⁻¹¹⁾

Lung adenocarcinoma does commonly presents with malignant pleural effusion. The hallmark of lung adenocarcinoma in the histopathological examination is the positive TTF-1 and Napsin A immunohistochemistry stains, which help to confirm the diagnosis of lung primary. Other markers such as Claudin-4, MOC31, BG8 (LewisY) and BER-EP4 have a high yield of diagnosis as well.⁽¹²⁾

One of the important differential diagnoses of MPM is renal cell carcinoma, as there is 1-2% of malignant pleural effusion diagnosed eventually as metastatic renal cell carcinoma⁽¹³⁾. Usually, patients with renal cell carcinoma will have positive stains of PAX8, PAX2, Claudin 4 and CD 15 in their histopathological examination.⁽¹²⁾ Lymphoma was also excluded with negative hemolympoid immunohistochemistry (LCA, CD3, CD20, CD15, CD30, PAX5, Mum1, CD21, CD23, BCL2, BCL6, and CD138).

Conclusion

Histological and immunohistochemistry examination of our patient's biopsy did not show any positivity for MPM or its common mimics. There was no clear evidence of a specific line of differentiation which make treatment very difficult. Therefore it was labeled as an undifferentiated epithelioid malignant neoplasm. Unfortunately, our patient passed away shortly after his presentation as this undifferentiated lesion behaved aggressively.

References

1. Odgerel CO, Takahashi K, Sorahan T, Driscoll T, Fitzmaurice C, Yoko OM, et al. Estimation of the global burden of mesothelioma deaths from incomplete national mortality data. *Occup Environ Med.* 2017;74(12):851-8.
2. Janes SM, Alrifai D, Fennell DA. Perspectives on the Treatment of Malignant Pleural Mesothelioma. *N Engl J Med.* 2021;385(13):1207-18.

3. Szulkin A, Szatmári T, Hjerpe A, Dobra K. Chemosensitivity and resistance testing in malignant effusions with focus on primary malignant mesothelioma and metastatic adenocarcinoma. *Pleura Peritoneum*. 2016;1(3):119-33.
4. Shinohara T, Shiota N, Kume M, Hamada N, Naruse K, Ogushi F. Asymptomatic primary tuberculous pleurisy with intense 18-fluorodeoxyglucose uptake mimicking malignant mesothelioma. *BMC Infect Dis*. 2013;13:12.
5. Dawood W, La Garza Henriette D, Iliescu G, Moran C, Grosu H. Pleural tuberculosis mimicking malignant mesothelioma. *Respir Med Case Rep*. 2020;29:100964.
6. Xu T, Wang L, Zhou L, Wang Z, Zhu Y, Ju F. Primary colorectal diffuse large B-cell lymphoma initially presenting with pleural effusion: report of one case and review of literature. *Int J Clin Exp Pathol*. 2020;13(2):254-60.
7. Ito T, Fujita K, Okamura M, Okuno Y, Saito Z, Kanai O, et al. Pleural involvement of diffuse large B-cell lymphoma mimicking malignant pleural mesothelioma. *Respir Med Case Rep*. 2020;31:101206.
8. Romei C, Fanni SC, Volpi F, Milazzo A, D'Amore CA, Colligiani L, et al. New Updates of the Imaging Role in Diagnosis, Staging, and Response Treatment of Malignant Pleural Mesothelioma. *Cancers (Basel)*. 2021;13(17).
9. Inomata M, Kawagishi Y, Yamada T, Miwa T, Hayashi R, Kashii T, et al. [Two cases of pulmonary sarcomatoid carcinoma mimicking malignant mesothelioma]. *Nihon Kokyuki Gakkai Zasshi*. 2010;48(1):33-8.
10. Zhao S, Hou T, Li Q. Sarcomatoid carcinoma of the pleura: A case report. *Radiology of Infectious Diseases*. 2019;6(3):128-32.
11. Ciarallo A, Makis W, Novales-Diaz JA, Lisbona R. Sarcomatoid carcinoma (carcinosarcoma) of the lung mimics malignant pleural mesothelioma on 18F-FDG PET/CT: a report of 2 cases. *Clin Nucl Med*. 2012;37(4):416-9.
12. Husain AN, Colby TV, Ordóñez NG, Allen TC, Attanoos RL, Beasley MB, et al. Guidelines for Pathologic Diagnosis of Malignant Mesothelioma 2017 Update of the Consensus Statement From the International Mesothelioma Interest Group. *Archives of Pathology & Laboratory Medicine*. 2017;142(1):89-108.
13. Arain A, Swaminathan M, Kumar J. Renal Cell Carcinoma Presenting as Pleural Effusion. *Wmj*. 2019;118(1):49-51.