

Hyperthyroidism with Peritoneal Serositis Leading to Small Bowel Obstruction: A Rare Case Report

Ali Al Sharqi¹, Ruqaiya Al Shehhi^{2*}, Miaad Al Hinai³, Safiya Al Masrouri² and
Hani Al Qadhi²

¹Oman Medical Specialty Board, Muscat, Oman

²General Surgery Department, Sultan Qaboos University Hospital, Muscat, Oman

³Intern, Sultan Qaboos University Hospital, Muscat, Oman

Received: 7 May 2023

Accepted: 8 June 2023

*Corresponding author: r.alshehhi@squ.edu.om

DOI 10.5001/omj.2025.01

Abstract

Small bowel obstruction (SBO) in the virgin abdomen represents a unique entity. Identifying and promptly treating these cases is very crucial. On occasions, endocrinopathies may result in small bowel obstruction, usually functional, but maybe also mechanical. The pathophysiology of mechanical obstruction in patients with Grave's disease is not fully understood. Moreover, some literature suggests a link between autoimmune endocrinopathies and pan serositis or peritoneal inflammation, especially in patients who develop thyroid storms. In this case study, we present a young Woman with uncontrolled Grave's disease who was admitted with a small bowel obstruction in a virgin abdomen a few weeks after developing a thyroid storm.

Keywords: Hyperthyroidism, endocrinopathy, bowel obstruction.

Introduction

Small bowel obstruction (SBO) is exceptionally rare in a virgin abdomen and is crucial to treat cautiously. The main possible underlying causes of SBO in a virgin abdomen include congenital adhesions, internal hernia, pelvic inflammatory disease, endometriosis, and intestinal malrotation (1). In addition, occasions, Intestinal obstructions or pseudo-obstructions can be a clinical presentation of autoimmune endocrinopathy (2). The intestinal obstruction of hypothyroidism can be acute, subacute, or chronic and recurrent. However, the pathophysiology of adhesive SBO in patients with hyperthyroidism is not fully understood (2). In this case report, we present a young woman with intestinal obstruction in the background of uncontrolled hyperthyroidism.

Case report

A 31-year-old woman presented to the emergency department with three days history of abdominal pain, obstipation, nausea, and vomiting. She denied any history of fever, change in urinary habits, and no history of vaginal discharge. The rest of her systemic review was unremarkable. She was known to have Graves' disease treated with carbimazole 40 mg BID and propranolol 40 mg OD . However, she was not compliant with medications, because of which she was admitted with thyroid storm a few weeks prior to her presentation with intestinal obstruction symptoms. There was no past surgical history whatsoever.

On examination, the patient was hemodynamically stable, afebrile, and had no features of severe systemic hyperthyroidism. Her abdomen was mildly distended and soft but there was generalized tenderness. Bowel sounds were present, and the rest of the examination was otherwise unremarkable.

Laboratory investigations showed normal hemoglobin levels with normal inflammatory markers. Serum T4:11.0 pmol/L (normal range- 12.3 - 20.2 pmol/L), Thyroid Stimulating Hormone (TSH) of 0.01 mIU/L (normal range – 0.27 – 4.20 mIU/L), and electrolytes within normal range.

Ultrasound abdomen was done, ruled out ovarian torsion, and showed a significant amount of free fluid in the right iliac fossa extending to the Morison pouch and a moderate amount of pelvic free fluid. Computed tomography of the abdomen and pelvis with intravenous contrast was performed and showed distended stomach, duodenum, and proximal jejunal loops with air-fluid level and partial collapse of the distal bowel loops, omental fat stranding, moderate abdominal and pelvic ascites with thickened enhancing peritoneum suggestive of small bowel obstruction (Figure 1 a-d).

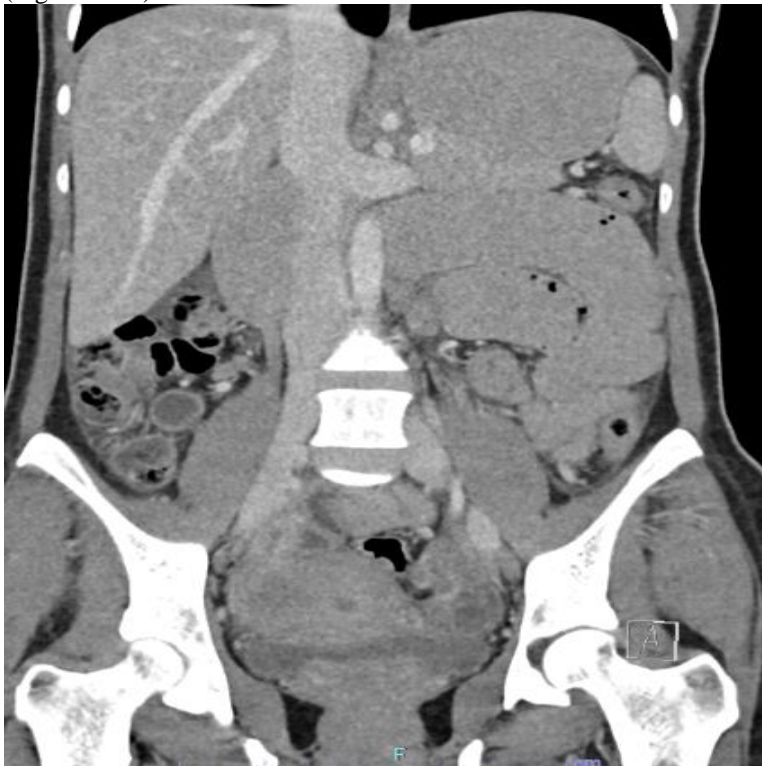

Figure 1a: Coronal view on CT scan showing multiple dilated bowel loops.

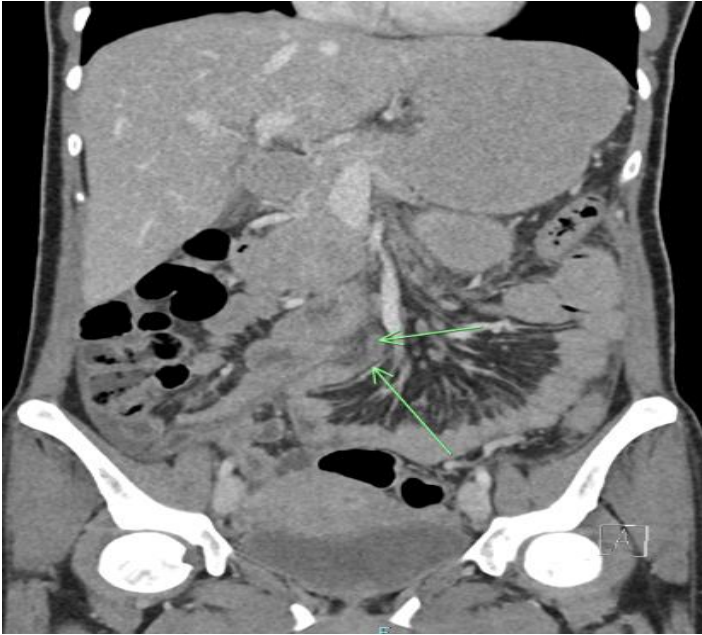

Figure 1b: Coronal view on CT scan showing transition point at proximal small bowel.

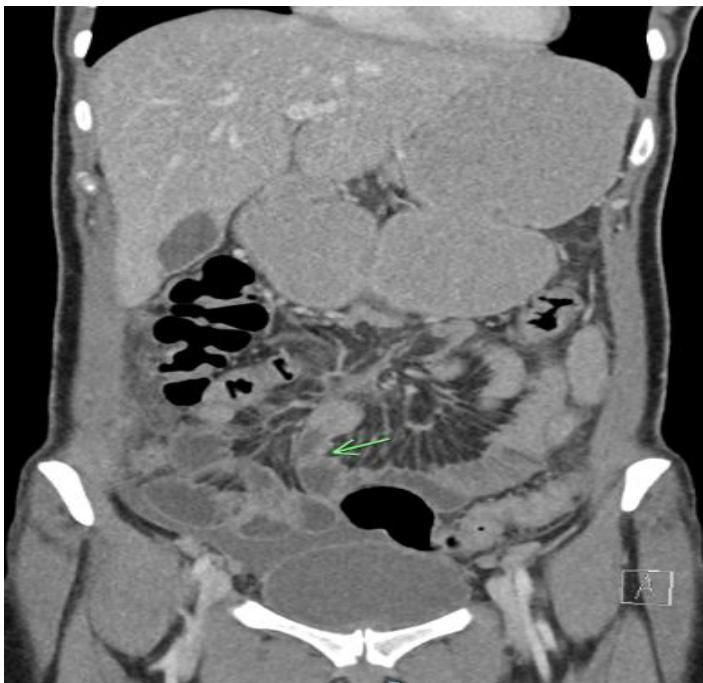

Figure 1c: Coronal view on CT scan showing another transition point

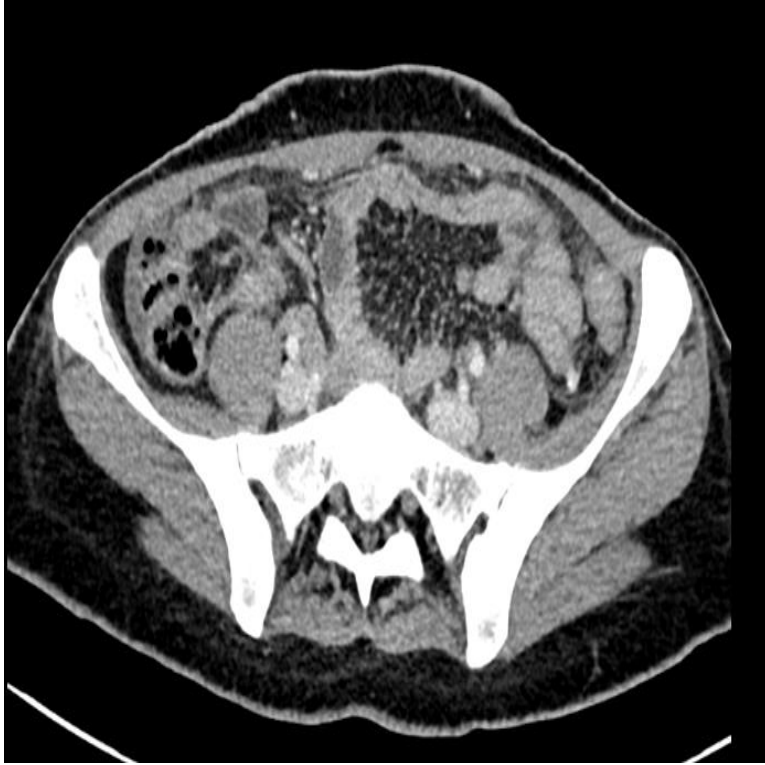

Figure 1d: Axial view on CT scan showing collapsed bowel loops in the pelvis

Given the absence of past abdominal surgical history with the clinical and radiological findings, the patient was consented and taken to the operating theatre for diagnostic laparoscopy after initial resuscitation. Intra-operative findings revealed diffuse soft fibrinous adhesions between the liver and abdominal wall, dilated proximal bowel with collapsed bowel distally, and soft bands causing narrowing of the proximal jejunum (Figure 2a-b). Adhesiolysis was carried out with a harmonic scalpel; the bowel was observed to distend after the release of the bands. Moreover, adhesions above the liver were released. The small bowel was run from the ligament of Treitz to the terminal ileum, and no other pathology was detected.

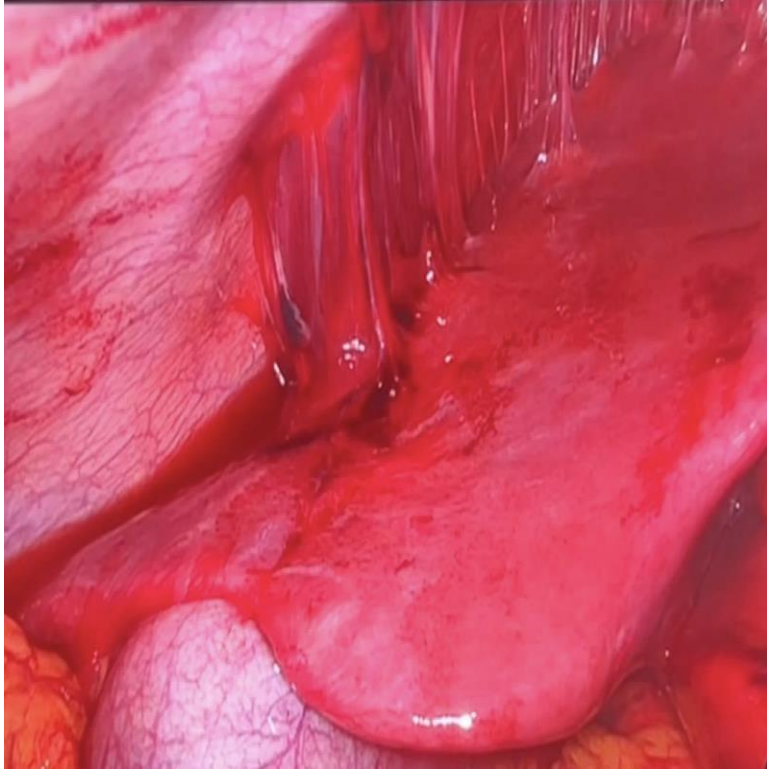


Figure 2a: Intraoperative finding of diffuse soft fibrinous adhesions between the liver and abdominal wall.

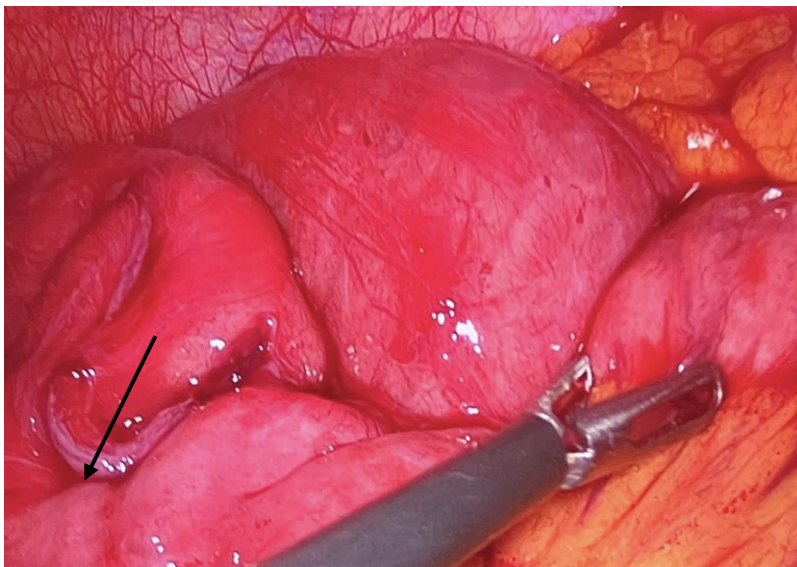


Figure 2b: Intraoperative finding of adhesive band around the bowel with congested dilated bowel proximal to the adhesion.

Given the medical history of the patient and the intraoperative finding, some labs were sent to rule out the possible differential diagnosis, including immunology, which was positive for antinuclear antibodies, AntiRO52, and Anti-Sjogren's syndrome antigen A, but negative investigation for pelvic inflammatory disease.

Postoperatively, the patient was doing well; she tolerated the oral diet and had normal bowel habits. Two days postoperatively, she was discharged home, and three weeks later, she was followed at an outpatient clinic, where she continued to make a good recovery.

Discussion

Bowel obstruction is a rare presentation of endocrinopathy (2,3). As a result, endocrinopathies are usually forgotten and overlooked in the emergency department settings when faced with a clinical picture of intestinal obstruction (2,4).

A rare presentation of endocrinopathy is bowel obstruction, and rarer when it causes mechanical bowel obstruction similar to our patient's presentation. Moreover, in the context of Hyperthyroidism, especially in patients who develop thyroid storm, the diagnosis could be confused as patients can present with acute abdomen, which can mimic SBO in some cases, for which the exact cause is unknown (5).

Thyroid hormones is generally metabolic hormones that have a role in gut motility and other metabolic activities (6). The digestive symptoms, including abdominal pain, intractable vomiting, and altered bowel habits, can be the only presentation of hyperthyroidism in the absence of cardinal features of the disease (7). These presentations can be misdiagnosed with bowel obstruction from the first encounter. In a recent study published by Khalid B et al., of a young patient with undiagnosed gut malrotation presented with signs and symptoms suggestive of bowel obstruction and turned to have thyrotoxicosis. They hypothesized that the obstruction resulted from increased small bowel motility due to a high level of thyroid hormones predisposing to obstruction (8). However, in our case, we speculate that the patient might have developed serositis during her thyroid storm, leading to SBO due to fibrinous adhesions, which is why this case is considered rare. The diagnosis was made after excluding all other possible diagnoses, including pelvic inflammatory disease, which can give similar intraoperative findings of fibrinous adhesions and perihepatitis.

Pan serositis is one of the entities associated with autoimmune endocrinopathies, including Grave's disease (9). Studies have shown that, in rare cases, it can cause pericardial effusion in (3-6% of cases), isolated ascites, or in some cases, translocation of intestinal bacteria causing peritonitis and eventually leading to SBO and or intraabdominal complications in (< 4% of cases), and pleural effusion. However, some of these occurrences in other patients are underestimated due to their little clinical significance (10). To the best of our knowledge, isolated graves' disease has not been reported as a cause of polyserositis, and it is usually part of the polyglandular autoimmune syndrome. However, the patient was negative for other Diabetes mellitus, adrenal disease and fungal infection.

While the presented case is an unusual presentation of such a medical entity, it is essential to remember that hyperthyroidism can lead to small bowel obstruction in some way or another, especially in the case of uncontrolled disease.

Conclusion

Bowel obstruction is a rare complication of autoimmune endocrinopathies. However, it is a diagnosis of exclusion especially in patients with multiple adhesions causing small bowel obstruction in the absence of other common etiologies. A clear understanding of the pathophysiology is not well described in literature, however, it is proposed to be related to serositis and peritoneal inflammation that could be potentially associated with autoimmune endocrinopathies.

Reference

1. Sia ZK, Trautman J, Yabe TE, Wykes J. A rare case of small bowel obstruction in a patient with endosalpingiosis, Fitz-Hugh-Curtis syndrome, and chlamydia trachomatis pelvic inflammatory disease. *Case Reports in Surgery*. 2022;2022:1–4
2. Bouomrani S , Lassoued N, Ben HM et al. Recurrent Intestinal Obstruction Revealing Hypothyroidism. *Archives of Gastroenterology and Hepatology*. 2018; 1(1) 22-25.
3. Hjarðem E, Jørgensen LN. Severe ileus due to hypothyroidism. *Ugeskr Laeger*. 2008;170(40):3144-5.

4. Hernández-Ramírez DA, Castellanos-Juárez JC, Romero T, Barragan-Rincón Á, Blanco-Benavides R. Mixedematous ileus; acute abdomen exacerbate. *Rev Gastroenterol Mex.* 2008;73(4):231-4
5. Karanikolas M, Velissaris D, Karamouzos V, Filos KS. Thyroid storm presenting as intra-abdominal sepsis with multi-organ failure requiring intensive care. *Anaesth Intensive Care.* 2009 Nov;37(6):1005-7.
6. Pokhrel B, Aiman W, Bhusal K: Thyroid Storm. StatPearls [Internet], Treasure Island (FL): StatPearls Publishing; 2021.
7. Daher R, Yazbeck T, Jaoude JB, Abboud B. Consequences of dysthyroidism on the digestive tract and viscera. *World J Gastroenterol.* 2009 Jun 21;15(23):2834-8.
8. Bashir K, Bakhsh ZK, Gad HA, Bashir MT, Elmoheen A. An unusual case of thyroid storm masquerading as an intestinal obstruction in a patient with malrotation of the gut. *Cureus.* 2021.
9. Harris E, Shanghavi S, Viner T. Polyserositis secondary to COVID-19: the diagnostic dilemma. *BMJ Case Reports CP* 2021;**14**:e243880
10. Bhatia J, Kamath V, Radhika B. A rare case of hypothyroidism in a male presenting as polyserositis. *APIK Journal of Internal Medicine.* 2019;7(2):25.