

Adult-Onset Seizures as the First Manifestation of Anti-Ds-Dna Negative Systemic Lupus Erythematosus: Diagnostic Considerations and Management

Oladotun Victor Olalusi^{1*}, Joseph Yaria², Ibukun Dedeke³ and I. Chukwuocha¹

¹Physician specialist/Neurology Senior Registrar, University College Hospital, Ibadan, Nigeria

²Consultant Physician and Neurologist, University College Hospital, Ibadan, Nigeria

³Consultant Physician/Rheumatologist, University College Hospital, Ibadan, Nigeria

Received: 5 July 2023

Accepted: 6 September 2023

*Corresponding author: oladotunvolalusi@gmail.com

DOI 10.5001/omj.2025.24

Abstract

Systemic lupus erythematosus (SLE) is a quintessential autoimmune disease once thought to be rare in Africans. It may affect any organ or tissue, synchronously or asynchronously. Neuropsychiatric manifestations of SLE (NPSLE) range from headaches, mood/behavioral disorders to seizures. There are documented reports of seizures accompanying the diagnosis of SLE, with varying prevalence according to specific regions. However, seizures rarely precede the diagnosis of SLE. We present a case report of a 19-year-old African female with adult-onset seizures preceding overt clinico-laboratory diagnosis of anti-dsDNA negative SLE. A preceding short course of anti-malarial and carbamazepine prompted early consideration of drug-induced lupus erythematosus (DILE). However, the clinical features of SLE progressed and persisted despite discontinuation of offending agents with negative anti-histone antibodies. Among high-risk groups, it is important to recognize SLE as a potential cause of adult-onset seizures. In the absence of clear offending agents, metabolic or structural disease, baseline ANA may be imperative in the diagnostic work up of such patients.

Keywords: SLE, Seizures, neuropsychiatric SLE, NPSLE, connective tissue disease, auto-immune disease, drug-induced lupus, Carbamazepine-induced SLE

Introduction

Systemic Lupus Erythematosus (SLE) is a quintessential autoimmune syndrome once thought to be rare in Africans.^{1,2} It affects every organ and tissue, synchronously or asynchronously. Genetic predisposition, environmental triggers, and hormonal factors, play a role in the complex pathophysiology of the disease as well as in disease activity. Clinical manifestations and the pattern of organ involvement are protean, thus reflecting the complex mosaic of pathophysiologic pathways converging into the SLE clinical phenotype.¹

Subclinical lung disease has been demonstrated in childhood-onset SLE in the Sultanate of Oman.³ Among the systemic autoimmune disorders, neurological manifestations have been most recognized and well-studied in SLE. Neurologic symptoms are less prevalent in other systemic inflammatory and autoimmune disorders.⁴ The American College of Rheumatology (ACR) Nomenclature for Neuropsychiatric SLE (NPSLE) provides case definitions for 19 neuropsychiatric syndromes seen in SLE, with reporting standards and recommendations for laboratory and imaging tests.^{5,6}

Literature is replete with reports of seizures accompanying the diagnosis of SLE, with prevalence ranging from 9.5% in Iran to 42.4% in Nigeria.^{7, 8,9,10} It is important to note that in most of these reviews and case reports, the diagnosis of NPSLE rarely preceded that of SLE. When neurologic symptoms like seizures manifest before SLE, preceding use of anti-seizure medications should prompt a consideration of drug-induced lupus like syndrome,¹¹ which has to be ruled out by further testing. We present a case report of a 19-year-old female with adult-onset seizures preceding overt clinico-laboratory features of anti-dsDNA negative SLE. We also highlight the differential diagnostic considerations and management of this patient.

Case Report

A 19-year-old lady was seen at the neurology out-patient clinic on account of new-onset seizures, described as focal to bilateral tonic-clonic involvement of the limbs. The seizures started with right-sided facial twitches and jerky movements of the right hand. This was followed by abnormal breathing and phonation, eventually culminating in generalized tonic-clonic convulsion lasting approximately 2-3 minutes. There was ensuing post-ictal sleep lasting approximately 15 minutes. There were also reports of upward rolling of the eyes, teeth clenching, but no tongue biting, excessive salivation, or sphincteric disturbance. She had a total of four episodes prior to the initial review and had no headaches or premonitory aura. Prior to onset of illness, she had a brief non-specific febrile illness that was treated empirically with parenteral artemether (150mg for three days). The blood film for malaria parasite obtained prior to treatment was negative. There was no accompanying neck stiffness, neck pain, light or sound hypersensitivity. There was no personal or family history of epilepsy, childhood febrile seizures, head trauma, intercurrent central nervous system (CNS) infections or previous vascular events. There were no motor or sensory deficits, visual disturbance, behavioral changes, cognitive or gait impairment. There was no photosensitive skin rash, joint pain, weight loss or drenching night sweat. She had no history to suggest renal or hepatic decompensation. She did not take alcohol, psychoactive substances or use tobacco in any form. She had no previously diagnosed medical comorbidities. She had no known family history of epilepsy. Pregnancy, birth, and attainment of developmental milestones were unremarkable. Clinical examination as well the neurological, cardiovascular, chest and abdominal findings were otherwise unremarkable. Examination of the skin and integuments showed no unusual skin growths, ash-leaf spots, Shagreen's patches or facial port-wine staining.

The complete blood count showed a leukocyte of 5,530/ul with a neutrophil count of 48.3%, lymphocyte count of 39.4% and the platelet count was 378,000/ul. A repeat blood film for malaria parasite was negative while the urinalysis was essentially normal. Serum calcium, uric acid, electrolytes, urea, creatinine, and liver enzymes were normal, but serum albumin level was 2.8 g/dl. Urinalysis showed sediments, leucocytes+++ , squamous epithelial cells++, bacteria ++ and sterile urine culture study.

An assessment of acute symptomatic seizures was considered and she was commenced on tab carbamazepine 400mg BD.

She presented at the clinic two weeks later (second visit) after two episodes of seizures since the last review despite being regular on prescribed medications. Further neurological exam revealed a conscious and coherent lady with no cranial nerve deficits, no signs of meningeal irritation and no long tract signs. The muscle bulk, tone, power, reflexes and sensory examinations were essentially normal. The cerebellar exam showed no nystagmus or saccades. There was no titubation or dysarthria. There was subtle dysdiadochokinesia and past pointing, but no intention tremor, rebound phenomenon or pendular knee jerk. The gait was essentially normal. An assessment of breakthrough seizures was made. Carbamazepine was stopped and switched to levetiracetam (keppra) 500 mg twice daily. Her chest radiograph as well as the electroencephalogram (EEG) were otherwise normal. The brain MRI showed multiple T2/FLAIR sub-centimeter white matter hyperintensities [Figure 1]. The erythrocyte sedimentation rate (ESR) as assessed by the Westergreen method was 50mm in the first hour. There were no further breakthrough seizures.

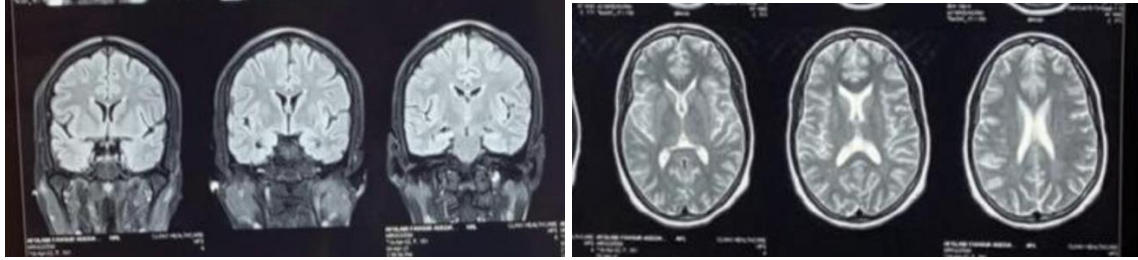


Figure 1: FLAIR corona and T2-weighted axial Brain MRI shows few sub-centimeter white matter hyperintensities.

Approximately three months after the first review (the third clinic visit), she reported exertional fatigue, breathlessness, worsening malaise, anorexia, and abdominal swelling. She was reported to have also had a brief spell of irrational behavior and aimless wandering few weeks prior. Besides, mild asterixis, the neurologic examination was essentially normal. The physical examination showed periorbital swelling, multiple well-circumscribed oval to round hyperpigmented maculopapular non-itchy skin rash on the trunk and proximal extremities [Figure 2]. There was malar (butterfly) rash sparing the nasolabial fold as well as scarring alopecia [Figure 2]. There was marked epigastric tenderness, abdominal swelling, and ascites. The urinalysis showed sediments and the serum urea and creatinine were elevated. A repeat ESR was 150mm in the first hour, serum anti-nuclear antibodies - 1:640 with low complement (C3, C4) levels. The anti-dsDNA as well as anti-histone antibody assays returned negative. Cerebrospinal fluid (CSF) studies (protein, glucose and microscopy) were essentially normal. The diagnosis was SLE with worsening renal function (uremia) secondary to lupus nephritis. She was managed conservatively.

Over the next several months, she manifested further target-organ involvement showing evidence of disease progression. The ultrasonography of the abdomen and pelvis showed right kidney size - 109x54mm, left kidney size - 127mmx65mm with loss of corticomedullary differentiation, ascites, bilateral pleural effusion suggestive of pancreatitis. Repeat urinalysis showed sediments - blood 3+, protein 3+. She was admitted and received pulse doses of methylprednisolone and was transitioned to oral prednisolone, mycophenolate mofetil (MMF) as well as hydroxychloroquine. She developed angioedema to MMF and this was switched to azathioprine. Months later, she was noted to have worsening ascites and respiratory difficulty (due to splinting of the diaphragm) with persistently low albumin levels. Paracentesis was attempted but unsuccessful. She received intravenous albumin infusion. She is currently receiving multidisciplinary care from a team of rheumatologist, nephrologist, and neurologist. She has remained seizure-free and currently on disease-modifying anti-SLE medications.

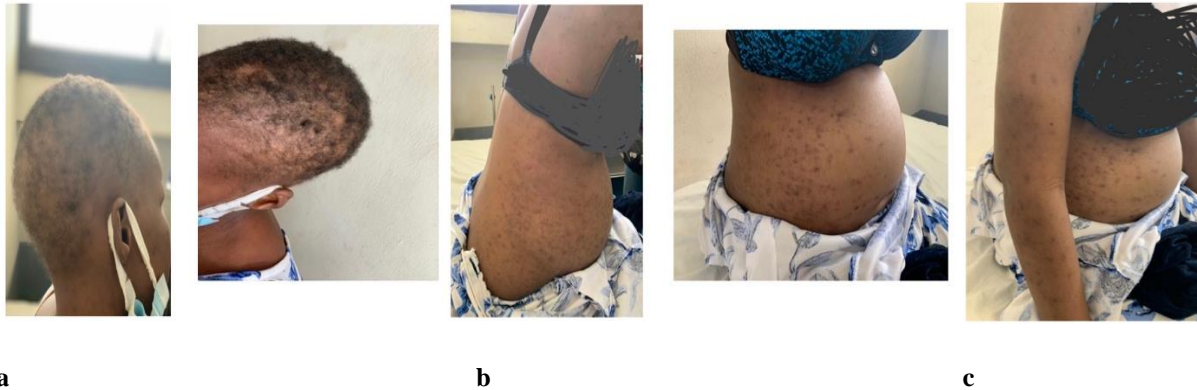


Figure 2: Three months after initial review. (a) Showing scarring alopecia. (b) Multiple well-circumscribed oval-round hyperpigmented macules and patches noted on the trunk and abdomen. (c) Multiple well-circumscribed oval-round hyperpigmented macules and patches also noted on the proximal extremities

Discussion

We have presented a case of a 19-year-old Nigerian female with adult-onset seizures diagnosed prior to overt clinico-laboratory features of anti-dsDNA negative SLE – using the 2019 EULAR/ACR diagnostic criteria. A prior short course of parenteral arthemeter and oral carbamazepine prompted early consideration of drug-induced lupus like syndrome.¹¹ However, this was ruled out by negative anti-histone antibodies and progression of SLE despite withdrawal of offending drug. The patient was referred to neurology clinic with seizures and only began to manifest features of an autoimmune illness three months later. This prompted an autoimmune screen using ANA. A retrospective review from a rheumatology clinic noted that a high index of suspicion is needed to diagnose SLE² while highlighting that concomitant presentation of neuropsychiatric manifestations and SLE may be not be uncommon. Therefore, among high-risk groups, baseline ANA may be beneficial as part of the diagnostic work up for adult-onset seizure disorder.

The 2019 EULAR-ACR classification criteria, used in this case, was developed using rigorous methodology with multidisciplinary and international input and has excellent sensitivity and specificity for the diagnosis of SLE. Use of ANA entry criterion, hierarchically clustered and weighted criteria accurately reflect current thinking about SLE and provides a basis for SLE research and diagnosis.¹² According to this criterion, our patient had the entry criteria of ANA: >1:80 (1:640) while meeting criteria across the clinical and immunologic domains. The constitutional symptoms of fever/malaise, neuropsychiatric features, mucocutaneous manifestation (scarring alopecia = 2), serositis (ascites and pleural effusion; score of 5), renal manifestations with 3+ proteinuria, and immunologic domains with low C3 and C4 gives a total score of 10.

The negative anti-dsDNA is a major highlight of this case and raised early concerns for drug-induced lupus erythematosus (DILE).¹³ While some antimalarials such as quinine are known to cause DILE, carbamazepine is a much rarer cause.^{14,15,16} Our patient had a 3-day course of artemether, which not known to cause DILE, and she did not receive quinine. She received a short course of carbamazepine 400mg bd and was seen two weeks later with subtle pass-pointing which is not uncommon with anti-seizure medications. Other aspects of the cerebellar examination were otherwise normal. Drug levels of carbamazepine could not be done due to financial constraints. She had breakthrough seizures which prompted a switch to levetiracetam.

Several months after carbamazepine was discontinued, she manifested florid symptoms of SLE with multi-organ involvement viz renal failure, pan-serositis, malar rash and symptomatic anemia. These symptoms persisted and progressed in the absence of an offending drug. Besides, anti-histone antibody, which is commonly found in DILE, was negative. If this were carbamazepine-induced SLE, the symptoms of SLE would be expected to improve following discontinuation of the offending drug. In addition, pan-serositis, renal compromise and hematologic findings are uncommon in DILE. Finally, DILE is typically found in older patients of Caucasian race while SLE is more common in young black patients.¹⁷ Our patient is a young black African – a high-risk population for idiopathic SLE.

Furthermore, we applied the Naranjo algorithm to estimate the causal relationship between carbamazepine and SLE in this case.¹⁸ This algorithm was used to classify 88 new cases of DILE in a publication from Denmark and divided cases into definite, probable, possible, or doubtful.¹³ A "definite" reaction was one that (1) followed a reasonable temporal sequence after a drug or in which a toxic drug level had been established in body tissues, (2) followed a recognized response to the culprit drug, and (3) was confirmed by improvement on withdrawing the offending drug and reappeared on exposure. A "probable" reaction (1) followed a reasonable temporal sequence after a drug, (2) followed a recognized response to the suspected drug, (3) was confirmed by withdrawal but not by exposure to the drug, and (4) could not be reasonably explained by the known characteristics of the patient's clinical state. A "possible" reaction (1) followed a temporal sequence after a drug, (2) possibly followed a recognized pattern to the suspected drug, and (3) could be explained by characteristics of the patient's disease. A reaction was defined as "doubtful" if it was likely related to factors other than a drug. Even though, there appears to be a temporal sequence in our case, the link between carbamazepine and SLE falls under the possible-doubtful category. Carbamazepine, unlike hydralazine, isoniazid and procainamide, is not a well-recognized cause of DILE and there was no improvement on discontinuing the drug in our patient. Lastly, the short-course of antimalarial (artemether) and carbamazepine used in this case are not likely to be the cause of our patient's autoimmune illness as DILE is not typically associated with severe SLE as seen in this index case.¹¹

In a retrospective review by Adelowo et al, out of a total of 1,250 rheumatology cases seen over a period of 6 years, 5.25% accounted for SLE with a 95.5% female preponderance and a mean of 33 years at presentation.² The mean duration of symptoms was 2.6 years with polyarthralgia, fever and hair loss being the most common presentation. Neuropsychiatric presentations were reportedly common, however this did not precede the diagnosis of SLE, as was documented in this case. In a follow up review by the same author, out of a total of 64 subjects diagnosed with SLE, thirty-three subjects (51.6%) had features of NPSLE. Headache was the commonest presentation (66.6%) while other common presentations were seizures (42.4), psychosis (30.3%).⁷ Our patient had adult-onset seizures and psychosis months before overt clinical features of SLE. In another prospective of 146 pediatric subjects with SLE from Iran, 41 (28%) had NPSLE with the most common neuropsychiatric symptoms being headache (13%), seizure (9.5%) and chorea (3.4%), others were migraine and depression. From the 41 patients with NPSLE, 18 (43.9%) presented with symptoms at the time of diagnosis; 10 (24.4%) showed NPSLE within one year of SLE diagnosis; while thirteen (31.7%) patients, developed neurological symptoms more than 1 year after the diagnosis of SLE.⁸

A recent case report from also highlighted a diagnosis of NPSLE concomitantly diagnosed in a Nigerian teenager.⁹ The patient had persistent headache, anxiety, confusion and generalized tonic-clonic seizures. It is important to note that in this reviews and case report, the diagnosis of NPSLE did not precede that of SLE. In turkey, a case report of a 7-year-old girl who had no initial history of seizure presenting with Status epilepticus, without clinico-laboratory findings of SLE (except for anemia) has also been documented.¹⁰ In addition, our patient had behavioral symptoms described as brief moments of irrational behavior and aimless wandering. This was attributed to uremic encephalopathy as she had clinical asterixis and deranged renal biochemical parameters. The CSF studies showed no evidence of inflammation or autoimmune encephalitis. Other diagnostic considerations entertained were lupus cerebritis and brief manic episodes which may be due to levetiracetam.^{19,20} Besides, seizures may also be associated with neuropsychiatric disorders. In a recent publication from the UAE, depressive symptoms were endorsed in 52.0% of children living with epilepsy, despite compliance with medications.²¹ The type of epilepsy was significantly associated with the presence of depressive symptoms.²¹

In a recent study of a cohort of 519 consecutive patients with SLE, followed up for 4 - 7.8 years, sixty (11.6%) patients with epileptic seizures were identified and epileptic seizures occurred at the onset of SLE symptoms in 19 (31.6%) and after the onset of SLE in 41 of 60 (68.3%) patients. Fifty-three of 60 (88.3%) patients had acute symptomatic epileptic seizures, and 7 of 60 (11.7%) had recurrent epileptic seizures.²² In a review of factors associated with time-to-seizure occurrence occurring at or after diagnosis of systemic lupus erythematosus, younger age and disease activity were independent predictors of a shorter time-to-seizure occurrence; antimalarials appear to have a protective role in seizure occurrence.²³ Our patient was young and appeared to have high disease activity evidenced by the low complement levels. She also received antimalarials at onset of illness. The effect of antimalarials on seizure occurrence however is yet unclear.

Neuropsychiatric SLE and association with specific autoantibodies have also been described. One of such is antiphospholipid antibodies associated with acute epileptic seizures at SLE onset.²² This is important as our patient had anti-dsDNA negative antibodies. In a study from western India, Anti-Rib-P antibodies as well as anti-neuronal antibodies did not show statistically significant correlation with neuropsychiatric manifestations in NPSLE patients.²⁴ In another study, anti-dsDNA status influences the clinical and immunological features of SLE patients. Nonetheless, it does not appear to affect disease activity.²⁵ In a large single-center study, serositis was seen more frequently in patients with anti-dsDNA negative (82.3%) compared to anti-dsDNA positive.²⁵ This was demonstrated in our patient as she had refractory ascites and pleural effusion requiring drainage.

The low serum albumin finding of 2.8 g/dl in our patient is a negative acute phase reactant in light of the underlying inflammatory process. This was also supported by the urinalysis finding showing sterile pyuria with prominent gastrointestinal symptoms raising concerns for a possible lupus cystitis which has also been widely reported in literature.^{26,27} Lupus cystitis can precede SLE diagnosis and may present with very unspecific urinary and digestive tract symptoms or no symptoms at all.²⁸ The exact mechanism of bladder inflammation in lupus is not fully understood, however, histopathological studies suggest a possible role of immune complex-mediated small vessel vasculitis.²⁶ Immune-complex mediated small vessel vasculitis in SLE has helped to explain the myriad of systemic inflammatory manifestations involving the skin, joints, renal, hematologic as well as the neurologic system, which were manifest in our index patient.

Conclusion

Among high-risk groups, idiopathic SLE should be excluded as potential cause of adult-onset seizures. In the absence of clear offending agents, metabolic or structural disease, baseline ANA is imperative in the diagnostic evaluation of such patients.

Disclosure

The authors have no multiplicity of interests to disclose. Written informed consent was obtained from the patient for publication of this case report and any accompanying images.

References

1. Fava A, Petri M. Systemic Lupus Erythematosus: Diagnosis and Clinical Management. *J Autoimmun.* 2019 Jan;96:1–13.
2. Adelowo OO, Oguntona SA. Pattern of systemic lupus erythematosus among Nigerians. *Clin Rheumatol.* 2009 Jun;28(6):699–703.
3. Abdulla E, Al-Zakwani I, Baddar S, Abdwani R. Extent of subclinical pulmonary involvement in childhood onset systemic lupus erythematosus in the sultanate of oman. *Oman Med J.* 2012 Jan;27(1):36–9.
4. Hanly JG, Urowitz MB, Sanchez-Guerrero J, Bae SC, Gordon C, Wallace DJ, et al. Neuropsychiatric events at the time of diagnosis of systemic lupus erythematosus: an international inception cohort study. *Arthritis Rheum.* 2007 Jan;56(1):265–73.
5. The American College of Rheumatology nomenclature and case definitions for neuropsychiatric lupus syndromes. *Arthritis Rheum.* 1999 Apr;42(4):599–608.
6. Nived O, Sturfelt G, Liang MH, De Pablo P. The ACR nomenclature for CNS lupus revisited. *Lupus.* 2003;12(12):872–6.
7. Adelowo OO, Oguntona AS, Ojo O. Neuropsychiatric systemic lupus erythematosus among Nigerians. *Afr J Med Med Sci.* 2009 Mar;38(1):33–8.
8. Khajezadeh MA, Zamani G, Moazzami B, Nagahi Z, Mousavi-Torshizi M, Ziaee V. Neuropsychiatric Involvement in Juvenile-Onset Systemic Lupus Erythematosus. *Neurology Research International.* 2018 May 29;2018:1–7.
9. Ojo O, Omisore-Bakare M. Neuropsychiatric lupus in a Nigerian teenager. *African Journal of Rheumatology.* 2018 Apr 24;6(1):23–5.
10. İncecik F, Hergüner MÖ, Yılmaz M, Altunbaşak Ş. Systemic Lupus Erythematosus Presenting with Status Epilepticus: A Case Report. *Arch Rheumatol.* 2012;27(3):205–7.
11. Vaglio A, Grayson PC, Fenaroli P, Gianfreda D, Boccaletti V, Ghiggeri GM, et al. Drug-induced lupus: Traditional and new concepts. *Autoimmun Rev.* 2018 Sep;17(9):912–8.
12. Aringer M, Costenbader KH, Daikh DI, Brinks R, Mosca M, Ramsey-Goldman R, et al. 2019 EULAR/ACR Classification Criteria for Systemic Lupus Erythematosus. *Arthritis Rheumatol.* 2019 Sep;71(9):1400–12.
13. Laurinaviciene R, Sandholdt LH, Bygum A. Drug-induced cutaneous lupus erythematosus: 88 new cases. *Eur J Dermatol.* 2017 Feb 1;27(1):28–33.
14. Vedove CD, Del Giglio M, Schena D, Girolomoni G. Drug-induced lupus erythematosus. *Arch Dermatol Res.* 2009 Jan;301(1):99–105.
15. Katz U, Zandman-Goddard G. Drug-induced lupus: an update. *Autoimmun Rev.* 2010 Nov;10(1):46–50.
16. Sarkar R, Paul R, Pandey R, Roy D, Sau TJ, Mani A, et al. Drug-induced Lupus Presenting with Myocarditis. *J Assoc Physicians India.* 2017 Jun;65(6):110.
17. Solhjoo M, Goyal A, Chauhan K. Drug-Induced Lupus Erythematosus. In: *StatPearls* [Internet] [Internet]. StatPearls Publishing; 2023 [cited 2023 Aug 28]. Available from: <https://www.ncbi.nlm.nih.gov/books/NBK441889/>
18. Naranjo CA, Busto U, Sellers EM, Sandor P, Ruiz I, Roberts EA, et al. A method for estimating the probability of adverse drug reactions. *Clin Pharmacol Ther.* 1981 Aug;30(2):239–45.

19. Park EM, Holmes JA, Reeder-Hayes KE. Acute mania associated with levetiracetam treatment. *Psychosomatics*. 2014;55(1):98–100.
20. Altınöz AE, Tosun Altınöz Ş, Güzel Biltekin B, Can Kaya M. Levetiracetam induced hypomania: a case report. *Ther Adv Drug Saf*. 2019;10:2042098619876754.
21. Al Kiyumi H, Al-Huseini S, Mirza H, Al Balushi N, Al-Risi K, Al Toubi A, et al. Depressive Symptoms and Its Correlate Among Children with Epilepsy at Single-center Study in Oman. *Oman Med J*. 2021 Nov 30;36(6):e329–e329.
22. Appenzeller S, Cendes F, Costallat LTL. Epileptic seizures in systemic lupus erythematosus. *Neurology*. 2004 Nov 23;63(10):1808–12.
23. Andrade RM, Alarcón GS, González LA, Fernández M, Apte M, Vilá LM, et al. Seizures in patients with systemic lupus erythematosus: data from LUMINA, a multiethnic cohort (LUMINA LIV). *Ann Rheum Dis*. 2008 Jun;67(6):829–34.
24. Pradhan V, Patwardhan M, Rajadhyaksha A, Dhawale N, Ghosh K. Neuropsychiatric manifestations and associated autoantibodies in systemic lupus erythematosus patients from Western India. *Rheumatol Int*. 2015 Mar;35(3):541–5.
25. Fabrizio C, Fulvia C, Carlo P, Laura M, Elisa M, Francesca M, et al. Systemic Lupus Erythematosus with and without Anti-dsDNA Antibodies: Analysis from a Large Monocentric Cohort. *Mediators of Inflammation*. 2015 May 6;2015:e328078.
26. Liberski S, Marczak D, Mazur E, Miętkiewicz K, Leis K, Gałązka P. Systemic lupus erythematosus of the urinary tract: focus on lupus cystitis. *Reumatologia*. 2018;56(4):255–8.
27. Mukhopadhyay S, Jana S, Roy M, Chatterjee A, Sarkar A, Mazumdar S, et al. Lupus cystitis: An unusual presentation of systemic lupus erythematosus. *Indian J Nephrol*. 2014;24(5):308.
28. Min JK, Byun JY, Lee SH, Hong YS, Park SH, Cho CS, et al. Urinary bladder involvement in patients with systemic lupus erythematosus: with review of the literature. *Korean J Intern Med*. 2000 Jan;15(1):42–50.