

Case Report: Osteoid Osteoma Mimicking Brachial Plexopathy in a Child

Asmaa Al-Furqani¹, Basit Salam² and Fatema Al-Amrani^{3*}

¹College of Medicine, Sultan Qaboos University, Muscat, Oman

²Department of Radiology and Molecular Imaging Department, Sultan Qaboos University Hospital, Muscat, Sultanate of Oman

³Pediatric Neurology Unit, Department of Child Health, Sultan Qaboos University Hospital, Muscat, Oman

Received: 23 July 2023

Accepted: 8 October 2023

*Corresponding author: famrani@squ.edu.om

DOI 10.5001/omj.2025.33

Abstract

Osteoid osteoma is a benign bone tumor with seventy percent of osteoid osteomas develop in people under the age of 20. Furthermore, osteoid osteoma is uncommon in children less than the age of 5, with an incidence of 3%. It affects long bones and usually presents with nocturnal pain that can be treated with non-steroidal anti-inflammatory drugs. It is uncommon for osteoid osteoma to present with weakness. We are reporting a case of a 4-year-old boy who has had right arm weakness for a period of three months, in addition to floppiness and localized discomfort on the proximal arm. He was found to have proximal and distal muscle weakness in addition to widespread muscle atrophy involving the affected arm. A needle exam was inconclusive, but neurophysiological investigations revealed low compound muscle action potentials in several nerves on the affected arm. Brachial plexus and cervical spine magnetic resonance imaging findings were normal. However, the child was found to have osteoid osteoma on the humerus of the affected side. All his symptoms, including muscle weakness, had reversed after surgical treatment of the osteoid osteoma.

Keywords: Osteoid osteoma, benign tumor, brachial plexopathy.

Introduction

Osteoid osteoma is the third most common benign bone tumor accounting for 10%- 14% of all benign bone tumors and 2% to 3% of primary bone tumors. It predominantly occurs in the long bones of the appendicular skeleton and specifically in the lower extremities.¹ It is usually seen in school-aged children and adolescents.² It is uncommon in children less than the age of 5, with an incidence of 3%.³

It usually presents with localized nocturnal pain that is alleviated by non-steroidal anti-inflammatory drugs.³ Other symptoms are variable and depends on the location of the osteoid osteoma. However, presentation in younger age groups (<5 years), is usually not typical and that may result in delayed diagnosis.⁴ The symptoms can include pain and limping when the lesion affects the lower extremities or can mimic osteomyelitis.^{4,5}

Neurological manifestations can be the presenting symptoms in patients affected by this benign tumor.⁶ In this report, we describe a patient with right humerus osteoid osteoma who presented with right arm weakness. This weakness was associated with localized muscle wasting and depressed deep tendon reflexes on the affected side, which highlights the diagnostic approach in this patient.

Case Report

A four-year-old male with an uneventful perinatal history and appropriate development presented with right-sided weakness for almost three months. Parents first noticed that the child does not move the right arm when running. Subsequently, parents noticed that the right arm was floppy. The patient also started complaining of pain in his arm that was partially relieved by massaging the proximal arm. Furthermore, the inability to move the right arm progressed, and the patient could not raise his right arm above 90 degrees above his shoulder. Moreover, he started waking up from sleep screaming from pain. There was no involvement of the lower extremities, ocular, bulbar, or facial muscles. Moreover, no further trauma and/or infectious symptoms were reported. Examination revealed a hypotonic right upper arm with a decrease in muscle bulk that involved the entire arm but predominantly proximal arm muscles. Muscle strength examination as per the Medical Research Council (MRC) scale showed 4/5 strength in shoulder abduction, elbow extension, elbow flexion, wrist extension, finger extension, and extensor indicis, whereas full power is obtained in the flexor digitorum profundus and the flexor digitorum superficialis. The working diagnosis at that point was a lower motor neuron lesion, and from a localization perspective, the prospective brachial plexus was the first consideration.

Nerve conduction studies (NCS) and electromyography (EMG) were performed. The NCS showed low compound muscle action potentials (CMAPs) involving ulnar, radial, musculocutaneous, and axillary nerves with normal distal latencies and conduction velocities. Sensory nerves were normal with no evidence of involvement. A needle exam performed on the right deltoid showed no spontaneous activity and normal motor units. This picture was not in keeping with the brachial plexus pattern; however, this possibility cannot be ruled out completely. A possible plexopathy was the working diagnosis; thus, magnetic resonance imaging (MRI) of the brachial plexus and cervical spine was performed, which showed no compressive lesions or enhancements in the cervical spine or brachial plexus. However, a focal area of signal abnormality was incidentally seen in the diaphysis of the right humerus with adjacent edema in the muscle as it was imaged partially and cannot be further characterized on that MRI.

X-ray of the right humerus showed a well-defined centric, slightly expansile, mixed density lesion in the diaphysis of the midshaft of the humerus with evidence of mild cortical resorption with no periosteal reaction, no soft tissue component, and no cortical disruption [Figure 1]. The patient was referred to a pediatric orthopedic surgeon for evaluation of the right humerus lesion that was found in the x-ray. Magnetic resonance imaging (MRI) and computed tomography (CT) findings were suggestive of a benign lesion of chondroid origin [Figure 2]. Therefore, a CT-guided biopsy was taken, and the result confirmed the diagnosis of osteoid osteoma. After 6 months of treatment with radiofrequency ablation and physiotherapy, the child regained his full right arm strength (5/5), and no muscle wasting was noted.

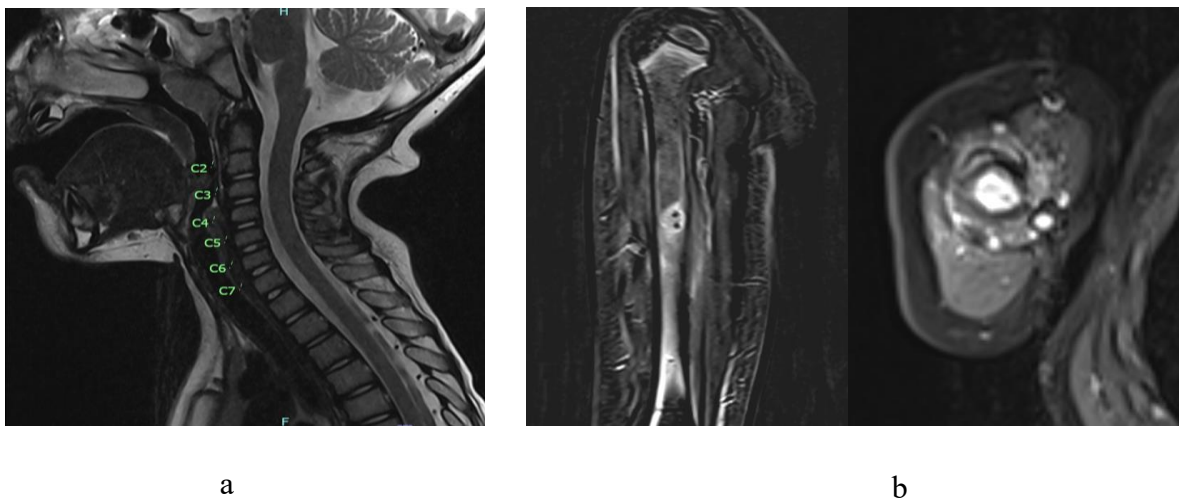


Figure 1: (a) MRI cervical spine including brachial plexus was normal. (b) MRI humerus showing enhancing lesion at midshaft of humerus

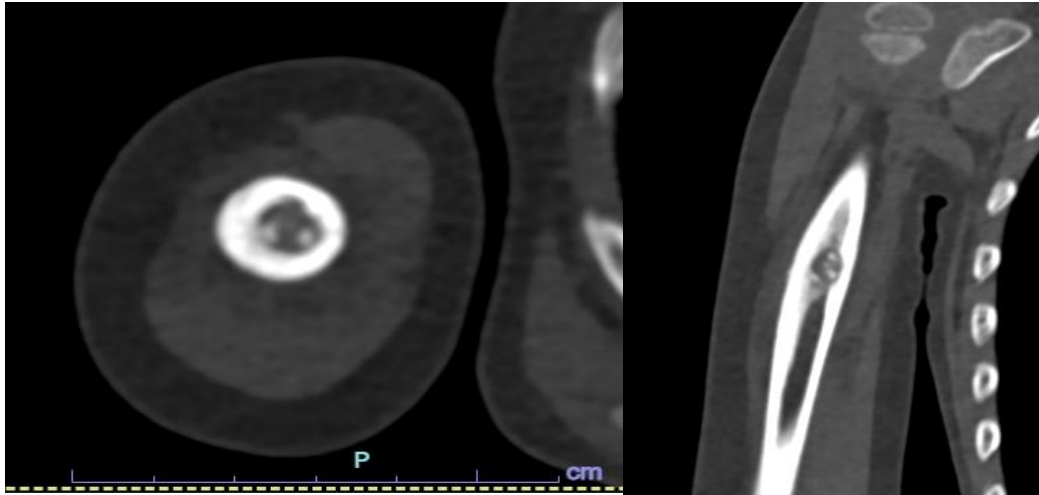


Figure 2: CT Axial and coronal sections showing lesion at mid diaphysis of humerus with thickened periosteum.

Discussion

Our patient presented with right arm weakness associated with generalized muscle atrophy. These symptoms were subsequently followed by the classic pain that is usually associated with osteoid osteoma. It is not uncommon for patients diagnosed with osteoid osteoma to present with neurological symptoms.³ Indeed, neurological symptoms can be the first manifestation of osteoid osteoma and can manifest prior to pain, which is considered a cardinal feature of this benign bone tumor.³ Keirs et al. reported seven pediatric patients with a confirmed histopathological diagnosis of osteoid osteoma involving the femur or tibia. All patients reported having localized muscle atrophy and/or depressed deep tendon reflexes.⁶ Moreover, another seven patients from the same cohort presented initially with neurological symptoms of abnormal gait and muscle wasting prior to their diagnosis. They were all evaluated by pediatric neurologists prior to their diagnosis.⁶ In addition, one patient from the Keirs et al. cohort with osteoid osteoma involving the proximal humerus presented with palpable swelling leading to compression of the brachial plexus on the same side.⁶ Our patient had no brachial plexus compression, as confirmed by brachial plexus MRI. The osteoid osteoma was not in close proximity to the brachial plexus to suggest a possible explanation for the compressive lesion causing right arm weakness; however, that was the first working diagnosis for this patient. The NCS and EMG pictures were not in keeping with the brachial plexus pattern of injury and this was further supported by the normal brachial plexus MRI, which showed no evidence of any compressive lesions. Moreover, around 30% of patients with osteoid osteoma in the cervical spine can present with neurological deficits.³ However, the osteoid osteoma in the case of this patient was not at the cervical spine. The symptoms of wasting and inability to move the right arm were likely related to the osteoid osteoma lesion itself and not to a compressive lesion on nerves or plexus. Pain probably played a role in the avoidance of movement on the affected arm, therefore, leading to the finding of muscle atrophy due to deconditioning and the impression of arm weakness. The underlying mechanism of depressed deep tendon reflexes and hypotonia was not clear; however, it was speculated that it was related to deconditioning that led to a state resembling focal myopathic process.

Additionally, there was no delay in the osteoid osteoma diagnosis of this patient; however, what was challenging was the right-arm weakness associated with his clinical presentation. In this report, muscle weakness was the initial and main complaint reported by parents and was followed by nocturnal pain at the time of presentation. There was significant muscle atrophy in the muscles of the right arm. The first report of muscle atrophy in osteoid osteoma was in 1979 in a four-and-a-half-year-old girl with left tibial osteoid osteoma.⁷ She was found to have atrophy of 2 cm of the left thigh and calf muscles with diminished left limb power.⁷ In 1993, Kaweblum et al. reported that 50% of their patient cohort with lower limb osteoid osteoma had muscular atrophy and 1 in 5 patients had a leg length discrepancy.⁸ In a retrospective review (from 1985 and 2000) of 48 patients with upper extremity osteoid osteoma, 46 patients reported persistent pain, and the other 2 only presented with swelling.⁹ Muscle weakness with atrophy has not been reported in this cohort.¹⁰ NCS and EMG in our patient showed low CMAPs in all motor nerves tested in the right arm, with sparing of the sensory nerves. That was attributed to muscle

atrophy. Needle examination did not support a neurogenic pattern. In addition, MRI of the cervical spine and brachial plexus showed no evidence of injury or any enhancement indicating inflammation. Therefore, brachial plexus involvement was excluded. Brachial plexus involvement can either be due to an acquired inflammatory process or a hereditary neuropathic process. Furthermore, follow-up a year after radiofrequency ablation for osteoid osteoma showed a normal exam with complete resolution of muscle atrophy and full strength.

In conclusion, we reported the case of a pediatric patient with humerus osteoid osteoma who presented initially with significant muscle atrophy and right arm pain. This atypical presentation in a challenging age group was misleading and can be confused with several neurological entities. Many cases had been reported regarding the variety of presentations that a patient with osteoid osteoma might present with, but only few reported muscles atrophy as one of the clinical features. When evaluating patients who present with weakness, it is important to consistently include non-neurological factors, such as pain, in the differential diagnosis.

References

1. Zhang Y, Rosenberg AE. Bone-Forming Tumors. *Surg Pathol Clin* 2017 Sep;10(3):513-535.
2. Kitsoulis P, Mantellos G, Vlychou M. <https://pubmed.ncbi.nlm.nih.gov/16768252/>. 2023 [cited 2023 Jun 30]. Osteoid osteoma - PubMed. Available from: <https://pubmed.ncbi.nlm.nih.gov/16768252/>
3. Tepelenis K, Skandalakis GP, Papathanakos G, Kefala MA, Kitsouli A, Barbouti A, et al. Osteoid Osteoma: An Updated Review of Epidemiology, Pathogenesis, Clinical Presentation, Radiological Features, and Treatment Option. *In Vivo* 2021;35(4):1929-1938.
4. Laliotis N, Chrysanthou C, Konstantinidis P, Papadopoulou L. Osteoid Osteoma in Children Younger than 3 Years of Age. *Case Rep Orthop* 2019 Sep;2019:8201639.
5. Bhat I, Zerlin JM, Bloom DA, Mooney JF III. Unusual presentation of osteoid osteoma mimicking osteomyelitis in a 27-month-old infant. *Pediatr Radiol* 2003 Jun;33(6):425-428.
6. Kiers L, Shield LK, Cole WG. Neurological manifestations of osteoid osteoma. *Arch Dis Child* 1990 Aug;65(8):851-855.
7. Black JA, Levick RK, Sharrard WJW. Osteoid osteoma and benign osteoblastoma in childhood.
8. 5. KM Lehman WB, Bash J, Strongwater A, Grant AD. <https://pubmed.ncbi.nlm.nih.gov/>. 1993 [cited 2023 Jul 1]. Osteoid osteoma under the age of five years. The difficulty of diagnosis - PubMed. Available from: <https://pubmed.ncbi.nlm.nih.gov/8222430/>
9. Themistocleous GS, Chloros GD, Benetos IS, Efstathopoulos DG, Gerostathopoulos NE, Soucacos PN. Osteoid osteoma of the upper extremity. A diagnostic challenge. *Chir Main* 2006 Jun;25(2):69-76.
10. Kaweblum WBLM J Bash. AD Grant,A Strongwater. <https://pubmed.ncbi.nlm.nih.gov/8127616/>. 2023 [cited 2023 Jul 1]. Diagnosis of osteoid osteoma in the child - PubMed. Available from: <https://pubmed.ncbi.nlm.nih.gov/8127616/>