

A Large Vulval Lesion During Pregnancy: Diagnostic Challenge

Chandana Prasad, Medha Davile*, Avantika Gupta and Shuchita Mundle

Department of Obstetrics and Gynecology, All India Institute of Medical Sciences, Nagpur, India

Received: 2 November 2023

Accepted: 15 February 2024

*Corresponding author: nagpure.medha@gmail.com

DOI 10.5001/omj.2024.73

A 21-year-old primigravida at 27 weeks of pregnancy presented with complaints of spotting per vaginum and a vulval mass. She had noticed the growth in the perineal region over the past two months, with an increase in size. The patient reported, good fetal movements and had no significant comorbidities. General and systemic examinations were unremarkable. On abdominal examination, the height of the uterus corresponded to the period of gestation, and fetal parts were palpable. Local examination of the vulva revealed a large cauliflower-like lesion containing multiple raised, skin-colored, fleshy papules measuring a few millimeters [Figure 1]. The lesion involved both labia majora, the lower part of the anterior vaginal wall near the urethral orifice, and the vaginal orifice around the fourchette. The lesion exhibited superficial keratinization and some bleeding points. Secondary infection was noted, with the formation of pus points. No other vaginal or cervical lesions were observed on per speculum examination.

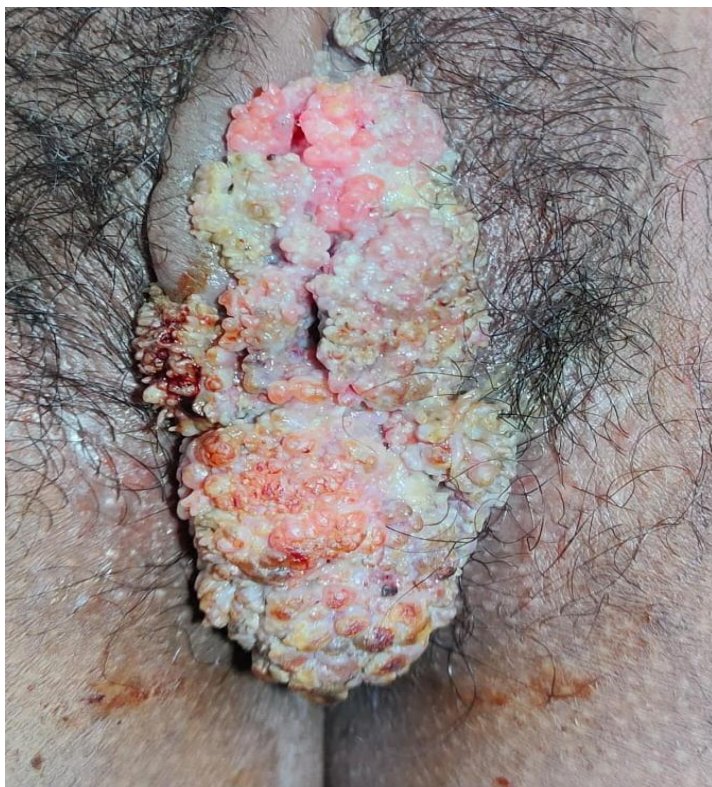

Figure 1: Vulval lesion on admission.

Question

What is the most likely diagnosis in this patient?

- a. Condyloma acuminata – It is a mucocutaneous manifestation of Human Papillomavirus (HPV) infection. Clinically, it presents as irregular, painless warty growths.
- b. Vestibular papillomatosis - These are digitiform proliferations of the mucosa surrounding a connective-vascular axis. These may extend along whole of the vestibule surrounding the inner aspect of the labia.
- c. Molluscum contagiosum - These are viral lesions caused by poxvirus. The lesions are usually multiple, small, skin colored papules with central umbilication.
- d. Angiokeratoma - It is acquired vascular tumor consisting of multiple, small, bluish reddish papules having smooth surface measuring 1-5 mm.
- e. Seborrheic keratosis - Giant seborrheic keratosis are verrucous lesions, rounded or oval with irregular surface but do not have koilocytes on histopathology.
- f. Giant condylomatosis or Buschke Lowenstein tumor - It is a benign, fast growing, exophytic genital lesion, with high capacity of local destruction.

Answer

- a. Condyloma acuminata – It is a mucocutaneous manifestation of Human Papillomavirus (HPV) infection. Clinically, it presents as irregular, painless warty growths.

Condyloma acuminata is predominantly caused by HPV types 6 and 11. It is a common sexually transmitted infection, with the highest incidence in women aged 20-24 years and men aged 25-29 years.¹ Risk factors include multiple sexual partners, early sexual debut, tobacco use, coexisting sexually transmitted diseases, immunocompromised status, lack of condom use, and low educational level.^{2,3} Clinically, the painless warty growth is often accompanied by discomfort, itching, foul-smelling discharge, and dyspareunia. In pregnancy, condyloma acuminata may exhibit larger and more numerous lesions, occasionally affecting the mode of delivery.

Discussion

Vertical transmission⁴ of human papillomavirus (HPV) during childbirth can occur through direct contact with maternal infected cells, whether during vaginal delivery or following early rupture of membranes in a cesarean section. In utero transmission may happen through an ascending infection from the mother's genital tract or via HPV-infected semen after intercourse. Transplacental transmission is supported by the presence of HPV DNA in amniotic fluid and has been detected in various tissues, including the endometrium, ovaries, placental cells, cord blood, and breast milk.

Treatment options⁵ for HPV during pregnancy encompass topical Imiquimod, cryotherapy, diathermy electrocoagulation, CO2 laser therapy, and surgical excision. Reports on using TCA as a single agent in pregnant women are scarce. Topical Imiquimod therapy spans 3-10 weeks, with local erythema being the most common side effect. Cryotherapy, requiring multiple sessions, may result in scars and pigment changes, posing a higher relapse risk for larger lesions. Diathermy electrocoagulation is effective for smaller warts but may cause permanent scarring in larger lesions. CO2 laser therapy, with a higher success rate, particularly in refractory cases and immunocompromised patients, carries a heightened risk of infection dissemination. The duration between treatment and recurrence being lowest following CO2 laser therapy and highest following imiquimod and cryotherapy.

In this specific case, surgical excision with a scalpel was chosen due to the relatively larger size of the lesion. This approach minimizes scarring and preserves healthy tissue, resulting in favorable outcomes (Figure 2A,B). HPV DNA testing was not done for this patient as it does not add to the management. Histopathology of the lesion

revealed markedly acanthotic papillomatosis, stratified squamous epithelium with hyperkeratosis. The papillae showed thin fibrovascular core with lining stratified squamous epithelium with koilocytic changes in the upper third of the epithelium (FIG 2 C,D). The patient underwent a caesarean section for fetal distress delivering a female baby weighing 2.5 kgs. Baby was well and patient was discharged on forth post-operative day. There were no genital lesions during this admission.

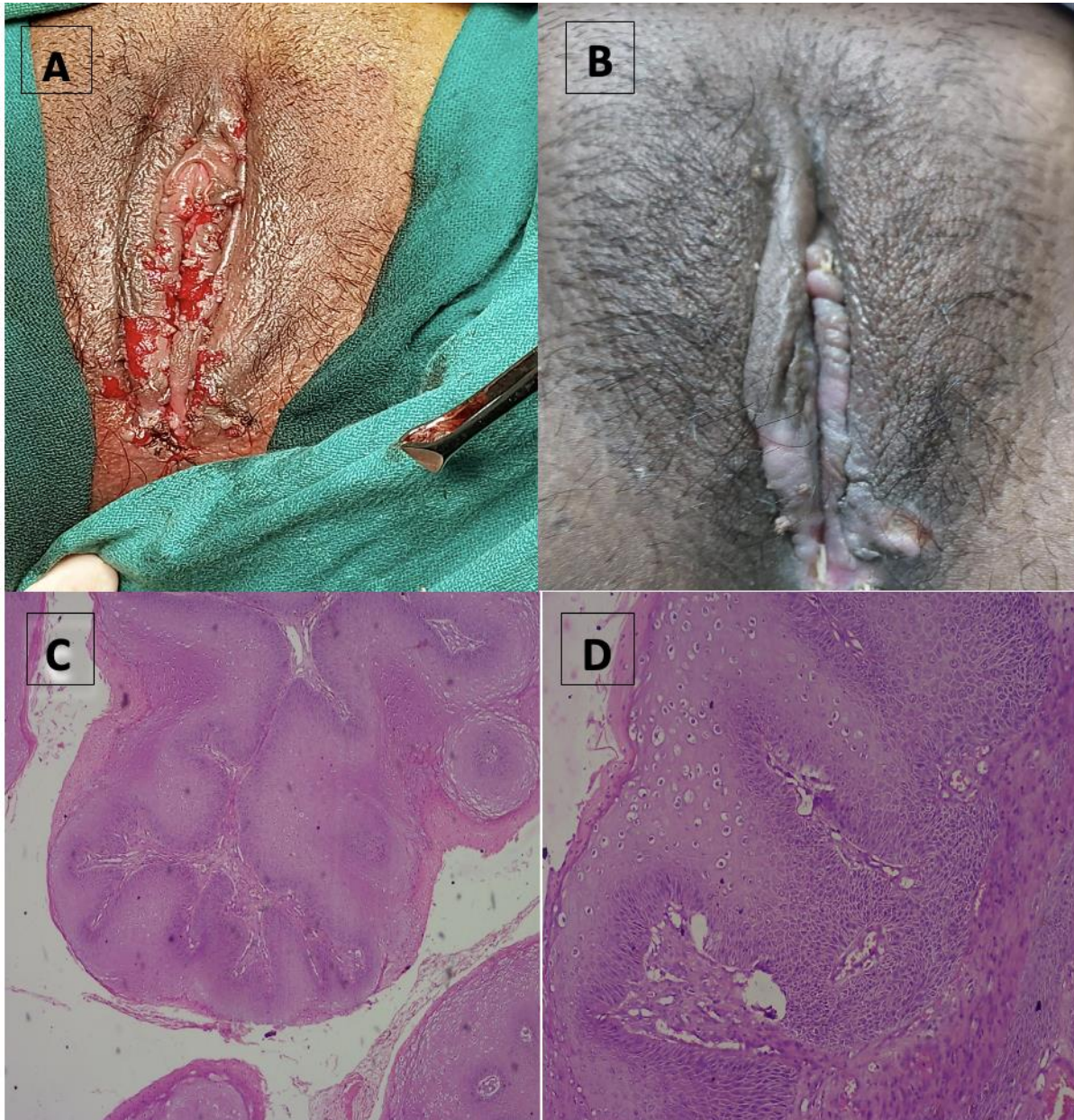


Figure 2: (a) Local examination of vulva after excision of the lesion, (b) local examination vulva two weeks after excision, (c) Showing hyperplastic papillary exophytic squamous epithelium with fibrovascular core(10x), and (d) Showing koilocytosis confined to upper third of squamous epithelium (40x).

Conclusion

This clinical quiz presents a challenging case of a 21-year-old pregnant patient with a large vulval lesion. The diagnosis of condyloma acuminata was based on clinical examination and histopathological findings. It emphasizes the importance of individualized treatment approaches, particularly during pregnancy. HPV vaccination remains the most effective preventive measure, and treatment should be tailored to the patient's unique

circumstances. Vertical mother-to-child transmission of HPV can occur in children born via a caesarean section.⁵ Caesarean section is indicated only when lesions obstruct the birth canal or pose a risk of excessive bleeding.

Condyloma acuminata presenting as a large vulval lesion during pregnancy poses a challenge for diagnosis and management. Other potential differential diagnoses should always be considered. The advantages and disadvantages of various treatment modalities for should be weighed and the patient managed accordingly.

Disclosure

Written **consent** was obtained from the patient and is available with the patient case sheet.

Acknowledgement

All authors declare that there are no conflict of interest including financial, relationships and affiliations.

References

1. Patel H, Wagner M, Singhal P, Kothari S. Systematic review of the incidence and prevalence of genital warts. *BMC Infect Dis*. Jan 25;13(1):39.
2. Goldstone S, Palefsky JM, Giuliano AR, Moreira ED Jr, Aranda C, Jessen H, et al. Prevalence of and risk factors for human papillomavirus (HPV) infection among HIV-seronegative men who have sex with men. *J Infect Dis* 2011 Jan;203(1):66-74.
3. Veldhuijzen NJ, Snijders PJ, Reiss P, Meijer CJ, van de Wijgert JH. Factors affecting transmission of mucosal human papillomavirus. *Lancet Infect Dis* 2010 Dec;10(12):862-874.
4. Trottier H, Mayrand MH, Coutlée F, Monnier P, Laporte L, Niyibizi J, et al. Human papillomavirus (HPV) perinatal transmission and risk of HPV persistence among children: Design, methods and preliminary results of the HERITAGE study. *Papillomavirus Res* 2016 Dec;2:145-152.
5. Sugai S, Nishijima K, Enomoto T. Management of Condyloma Acuminata in Pregnancy: A Review. *Sex Transm Dis*. 2021 Jun 1;48(6):403-409.