

Linezolid Induced Lactic Acidosis: A Case Report and Literature Review of a Rare Side Effect

Usama Al Amri¹, Zahra Al Shukri², Nuha Al Habsi², Jawahar Al Noumani^{1*},
Haitham Elbingawi¹ and Abdullah Balkhair³

¹General Medicine Unit, Department of Medicine, Sultan Qaboos University Hospital, Muscat, Oman

²Internal Medicine Residency Program, Oman Medical Specialty Board, Muscat, Oman

³Infectious Diseases Unit, Department of Medicine, Sultan Qaboos University Hospital, Muscat, Oman

Received: 3 June 2024

Accepted: 24 July 2024

*Corresponding author: jhsm41191@gmail.com

DOI 10.5001/omj.2026.38

Abstract

Linezolid is a synthetic antibiotic belonging to the oxazolidinone class. It can rarely cause life-threatening lactic acidosis which can progress to multi-organ dysfunction. We present a case of linezolid-induced life-threatening lactic acidosis after prolonged use. This patient was kept on linezolid for nocardiosis and he presented initially to our medical outpatient clinic with fatigability. Although he was normotensive, with no evidence of tissue hypo-perfusion on presentation, but his initial lactate was 11 and then 14 mmol/L which was obviously not related to sepsis or shock. This case highlights the need to be vigilant and to have a high index of clinical suspicion for linezolid induced lactic acidosis in patients receiving this drug, as in such cases immediate stop of linezolid is needed.

Keywords: linezolid, lactic acidosis, mortality

Introduction

Linezolid is a synthetic antibiotic belonging to the oxazolidinone class. It inhibits bacterial protein synthesis by binding to the ribosomal ribonucleic acid (rRNA). The US Food and Drug Administration authorized its use in 2000 after being introduced in 1996. Linezolid has been approved to treat gram-positive infections and nocardia species.^{1,2} The emergence of vancomycin-resistant enterococcal species has prompted the use of novel and modified therapeutic agents including linezolid and tigecycline, although resistance to those agents has already been reported in clinical settings.³ Mechanisms of linezolid resistance is due to mutations in the 23S ribosomal RNA (rRNA) genes and ribosomal protein-coding regulatory genes.⁴ The ramA efflux-related gene plays the major role in tigecycline resistance.⁵ Panton-Valentine Leukocidin Gene has been linked to community-associated methicillin resistant Staphylococci.⁶

There are several major adverse effects related to linezolid which include: neuropathy, myelosuppression, lactic acidosis, and hypoglycemia.¹ High levels of serum lactate may result in organ dysfunction with higher mortality. Lactic acidosis typically occurs because of inadequate tissue perfusion and oxygenation. However, lactic acidosis can also result from medications like linezolid, metformin, and nucleoside reverse-transcriptase inhibitors. [Lactic acidosis](#) is relatively rare side effect of linezolid and it has been reported in 6.8% of patients treated with this drug.⁷

We herein report a case of linezolid induced life-threatening lactic acidosis in elderly patient with multiple risk factors who was treated for disseminated nocardiosis. It is critical to suspect this diagnosis in patients on linezolid presenting with acidosis.

Case Report

An 83-year-old male, bedbound but communicating, was brought by his family to the medical outpatient department for a follow-up visit after an extended hospitalization due to pleuropulmonary nocardiosis. A few weeks earlier, he was discharged on an oral linezolid-based regimen for disseminated nocardiosis. He presented with one-week history of lethargy. He had no other symptoms. His medical history is significant for hypertension, ischemic stroke, vascular dementia, aortic stenosis, and benign prostate hyperplasia. The patient adhered to the prescribed linezolid course for 35 days. Initial clinical examination revealed an ill-looking man, dehydrated, BP 115/70 mmHg [Mean Arterial Pressure (MAP): 85 mmHg]. Cardiovascular examination reveals an ejection systolic murmur at the aortic area radiating to the carotids. Examination of the chest revealed bi-basal crepitation. Central nervous system examination indicated marked cognitive impairment consistent with known vascular dementia without focal neurological deficits. Skin examination reveals non-infected stage two sacral pressure ulcers. Other systemic examination was unremarkable.

Laboratory investigations revealed severe lactic acidosis (lactic acid:11.2 mmol/L) from initial venous blood gas, thrombocytopenia (platelet count: $58 \times 10^9/L$), anemia (hemoglobin: 8.5 g/dL), with normal White Blood Cell Count (WBC) $5.6 \times 10^9/L$ and Absolute Neutrophil Count (ANC) $3.9 \times 10^9/L$ and C-Reactive Protein of 118 mg/L. The initial venous blood gas showed: pH 7.21, PCO₂ 32.2 mmHg and HCO₃ 13.5 mmol/L. Biochemistry panel showed creatinine:78 $\mu\text{mol/L}$, bicarbonate (HCO₃): 12 mmol/L, Urea: 9.6 mmol/L, sodium: 130 mmol/L and potassium: 4.7 mmol/L [Table 1, Figure 1, 2]. Sputum, blood, urine, and wound cultures were sent considering the patient's clinical presentation without hypotension and laboratory findings, the primary clinical impression was linezolid-induced hyperlactatemia with lactic acidosis especially in the absence of other identifiable causes of lactic acidosis. Hence linezolid was discontinued and resuscitation with intravenous fluid was started. As his severe acidosis was not correcting with intravenous crystalloid fluid hydration and 200 ml of NaHCO₃, he then underwent a session of hemodialysis (with pre-dialysis serum lactate of 14 mmol/L and post dialysis lactate of 7 mmol/L).

Table 1: Laboratory investigations on admission.

Parameter	Result	Reference Range/Commentary
Serum Lactate	11 mmol/L	Normal: 0.5-2.2 mmol/L;
Platelet count	$58 \times 10^9/L$	Normal: $150-400 \times 10^9/L$;
Hemoglobin (Hb)	8.5 g/dL	Normal: 11.5-15.5 g/dL
White Blood Cell Count (WBC)	$5.6 \times 10^9/L$	Normal: $4.5-11.0 \times 10^9/L$
Absolute Neutrophil Count (ANC)	$3.9 \times 10^9/L$	Normal: $1.8-7.7 \times 10^9/L$
C-reactive protein (CRP)	118 mg/L	Normal: <5 mg/L; High,
Creatinine	78 $\mu\text{mol/L}$	Normal: 53-97 $\mu\text{mol/L}$
Estimated Glomerular Filtration Rate (eGFR)	85 mL/min/1.73m ²	Normal: >90 mL/min/1.73m ²
Bicarbonate (HCO ₃)	12 mmol/L	Normal: 22-29 mmol/L;
Urea	9.6 mmol/L	Normal: 2.5-7.1 mmol/L
Sodium	130 mmol/L	Normal: 135-145 mmol/L
Potassium	4.7 mmol/L	Normal: 3.5-5.1 mmol/L
Calcium	2.29 mmol/L	Normal: 2.15-2.55 mmol/L
Phosphate	0.82 mmol/L	Normal: 0.81-1.45 mmol/L
Magnesium	0.75 mmol/L	Normal: 0.66-1.07 mmol/L

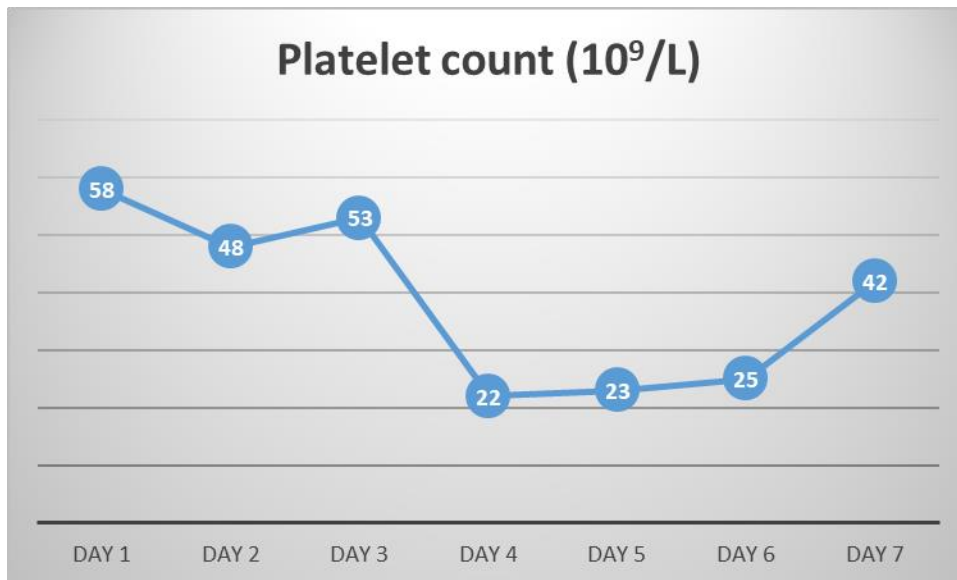


Figure 1: Trend of platelets count during admission.

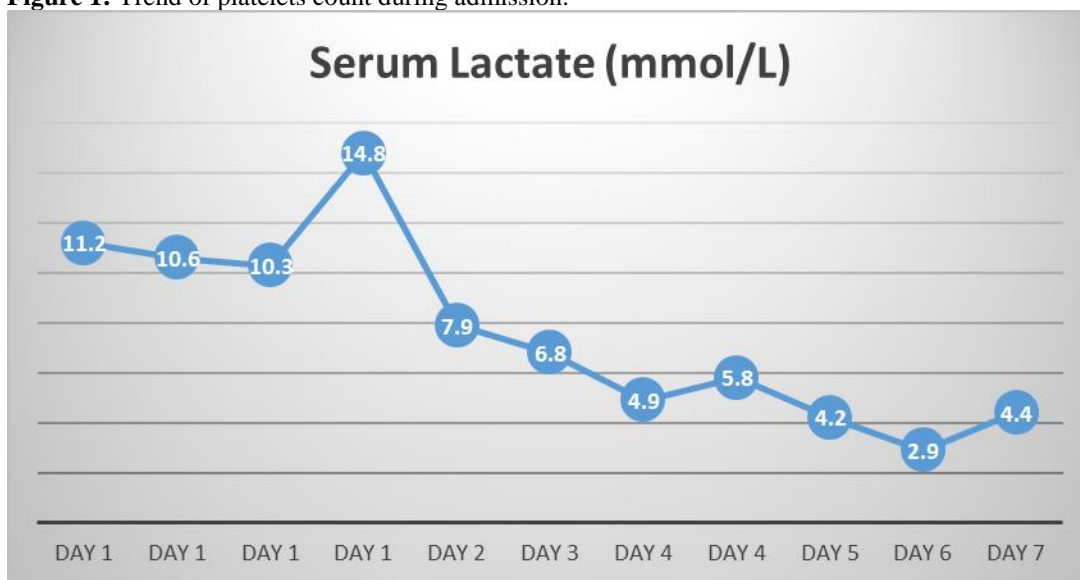


Figure 2: Trend of serum lactate levels during admission.

Despite the initial clinical and biochemical response following hemodialysis with improvement of hyperlactatemia and acidosis, by day 5 the patient developed hospital-onset pneumonia and refractory septic shock despite prompt initiation of empirical antimicrobials. He required noradrenaline by day 6 and subsequently died on day seven of admission. All cultures including blood cultures were negative.

Discussion

Linezolid is an oxazolidinone antimicrobial that inhibits protein synthesis by binding to 23S ribosomal RNA in the 50S subunit, preventing fusion with the 30S subunit and the initiation complex. It is used against multidrug-resistant gram-positive bacteria such as vancomycin-resistant enterococcus faecium, vancomycin-resistant Staphylococcus aureus, and methicillin-resistant Staphylococcus aureus.⁸

Less than 1% of patients on linezolid may experience myelosuppression including anemia, leukopenia, thrombocytopenia, or pancytopenia. Myelosuppression with linezolid (LZD) should be considered in elderly patients where drug-induced sideroblastic anemia (SA) could be confused easily with myelodysplastic syndrome (MDS). Monitoring of hematologic parameters is recommended in patients receiving long-term linezolid.⁹ Similarly, hypoglycemia, optic neuropathy, lactic acidosis, and multiorgan failure or death can rarely complicate linezolid use.^{2,10-13} Several factors increase the risk of linezolid induced toxicities including higher dosing, prolonged use (more than 28 days), baseline thrombocytopenia, and renal dysfunction.^{14,15}

The reported incidence of linezolid induced lactic acidosis was so wide in range between 2% and 33%^{16,17} based on study type, sample size and duration of exposure. It occurs due to a defect in oxygen consumption at the mitochondrial level in the absence of tissue hypoxia. In such case, the patient will have normal high venous oxygen saturation and normal to high oxygen delivery.^{7,16} The risk increases with higher dosing and with prolonged duration of treatment (duration >4 weeks) however Linezolid induced lactic acidosis may complicate relatively shorter exposure (2-4 weeks) or even soon after initiation of linezolid therapy (within 7 days) especially in immunocompromised patients and with comorbidities.^{7,18,19} Old age is also a recognized risk for linezolid induced lactic acidosis and earlier in the course of treatment.^{7,18} Due to the postulated link between cumulative linezolid level, it has been suggested that linezolid trough levels need be checked especially in high risk patient groups. Linezolid trough concentration of 2.5 mg/L maybe used as a target for therapeutic drug monitoring. However, there is no consensus on this and it is rarely practiced.¹¹

About 70% of linezolid is metabolized by the liver and the remaining is metabolized by the kidneys; therefore, liver dysfunction could precipitate linezolid induced lactic acidosis. It is stated that linezolid level is four to six folds higher in patients with liver dysfunction.^{7,15,18} This patient is free of this risk as his liver function was normal.

Other risk factors of linezolid induced lactic acidosis include high sequential organ failure assessment (SOFA) score, blood glucose >8 mmol/L, or being on proton pump inhibitors, amiodarone, or amlodipine.^{15,18}

Linezolid induced lactic acidosis has nonspecific symptoms, the most common are nausea and vomiting (33%), altered sensorium (27%), abdominal discomfort, diarrhea, generalized fatigability, and dyspnea. In severe cases, the patient may have circulatory collapse and a poor response to catecholamine administration with decreased myocardial contractility leading to death.^{7,15-17}

There is no definitive test to diagnose linezolid induced lactic acidosis, however, the level of lactic acid can point to the diagnosis in a patient with no other apparent etiologies for hyperlactatemia or acidosis. Linezolid induced hyperlactatemia typically remains high despite correcting the possible cause.¹⁶

The mainstay treatment for linezolid induced lactic acidosis is prompt cessation of the culprit drug which typically results in reversing the metabolic abnormalities in most cases within two weeks.^{15,16} However, in patients with severe renal impairment and acidosis other measures such as bicarbonate administration may be tried.¹⁵ In cases with severe linezolid induced lactic acidosis, renal replacement therapy can be used to improve acidosis and eliminate linezolid in addition to correcting other risk factors including thiamine deficiency, hypoxemia, and other concomitant toxic drugs.^{15,16} Sustained linezolid induced lactic acidosis carries a poor prognosis and is associated with unacceptably high mortality.^{7,18}

In this article, we reported a rare case of linezolid-induced lactic acidosis after prolonged exposure for treatment of extensive nocardiosis. This is a relatively rare side effect of linezolid but critical to be suspected in the appropriate clinical context with heightened vigilance. The causes for lactic acidosis are several and all shall be considered in the appropriate clinical settings (e.g. dehydration, hypotension, cellular toxicity, and hepatic failure). The diagnosis of linezolid induced lactic acidosis shall be considered among these differentials especially with prolonged use. In the present case, a diagnosis of linezolid induced lactic acidosis was made after through exclusion of other potential etiologies for severe hyperlactatemia and acidosis.

Conclusion

Linezolid-induced lactic acidosis is a rare but potentially fatal complication if unrecognized. Prompt cessation of linezolid upon suspicion and swift correction of acidosis are key in the management of this dreaded condition. Clinicians must be vigilant to suspect this rare but critical toxicity in patients receiving linezolid when presenting with unexplained hyperlactatemia and lactic acidosis.

References

1. Hashemian SM, Farhadi T, Ganjparvar M. Linezolid: a review of its properties, function, and use in critical care. *Drug Des Devel Ther* 2018 Jun;12:1759-1767.
2. Apodaca AA, Rakita RM. Linezolid-induced lactic acidosis. *N Engl J Med* 2003 Jan;348(1):86-87.
3. Zaheer R, Cook SR, Barbieri R, Goji N, Cameron A, Petkau A, et al. Surveillance of *Enterococcus* spp. reveals distinct species and antimicrobial resistance diversity across a One-Health continuum. *Sci Rep* 2020 Mar;10(1):3937.
4. Chen Q, Yin D, Li P, Guo Y, Ming D, Lin Y, et al. First report Cfr and OptrA co-harboring linezolid-resistant *Enterococcus faecalis* in China. *Infect Drug Resist* 2020 Nov;13:3919-3922.
5. Elgendy SG, Abdel Hameed MR, El-Mokhtar MA. Tigecycline resistance among *Klebsiella pneumoniae* isolated from febrile neutropenic patients. *J Med Microbiol* 2018 Jul;67(7):972-975.
6. Elgendy SG, Hameed WA, Hameed MR, Hassan AT. Detection of Pantom-Valentine Leukocidin Gene in Clinical Isolates of Staphylococci at Assiut University Hospitals. *Egypt J Med Microbiol* 2016;25(2). *EJMM* .
7. Zhang N, Zhang F, Chen Z, Huang R, Xia J, Liu J. Successful treatment of linezolid-induced severe lactic acidosis with continuous venovenous hemodiafiltration: A case report. *Saudi Pharm J* 2022 Feb;30(2):108-111.
8. Colca JR, McDonald WG, Waldon DJ, Thomasco LM, Gadwood RC, Lund ET, et al. Cross-linking in the living cell locates the site of action of oxazolidinone antibiotics. *J Biol Chem* 2003 Jun;278(24):21972-21979.
9. Saini N, Jacobson JO, Jha S, Saini V, Weinger R. The perils of not digging deep enough—uncovering a rare cause of acquired anemia. *Am J Hematol* 2012 Apr;87(4):413-416.
10. Miller HV, Cao AA, McClelland CM, Lee MS. Linezolid optic neuropathy. *Curr Opin Ophthalmol.* 2023;34(6):481-6. Epub 20230821. . PubMed PMID: 37603423.
11. Wasserman S, Brust JC, Abdelwahab MT, Little F, Denti P, Wiesner L, et al. Linezolid toxicity in patients with drug-resistant tuberculosis: a prospective cohort study. *J Antimicrob Chemother* 2022 Mar;77(4):1146-1154. .
12. Bouteille D, Grossi O, Depatureaux A, Tattevin P. Fatal lactic acidosis after prolonged linezolid exposure for treatment of multidrug-resistant tuberculosis. *Eur J Intern Med* 2009 Oct;20(6):e134-e135.
13. Contou D, Fichet J, Grimaldi D, Cariou A. Early life-threatening lactic acidosis following a single infusion of linezolid. 2011.
14. Boak LM, Rayner CR, Grayson ML, Paterson DL, Spelman D, Khumra S, et al. Clinical population pharmacokinetics and toxicodynamics of linezolid. *Antimicrob Agents Chemother.* 2014;58(4):2334-43. Epub 20140210. . PubMed PMID: 24514086; PubMed Central PMCID: PMC4023770.
15. Im JH, Baek JH, Kwon HY, Lee J-S. Incidence and risk factors of linezolid-induced lactic acidosis. *Int J Infect Dis* 2015 Feb;31:47-52.
16. Santini A, Ronchi D, Garbellini M, Piga D, Protti A. Linezolid-induced lactic acidosis: the thin line between bacterial and mitochondrial ribosomes. *Expert Opin Drug Saf* 2017 Jul;16(7):833-843.
17. Chen C-C, Liu W-T, Lin S-H. Lactic acidosis associated with standard dose linezolid in a kidney recipient with impaired renal function. *Braz J Infect Dis* 2022;26(1):101701.
18. Liu T, Hu C, Wu J, Liu M, Que Y, Wang J, et al. Incidence and Associated Risk Factors for Lactic Acidosis Induced by Linezolid Therapy in a Case-Control Study in Patients Older Than 85 Years. *Front Med (Lausanne)* 2021 Feb;8:604680.
19. Rehman HU. Linezolid-induced lactic acidosis. *Eur J Gen Med* 2016;13(2):149-151.