

# Abdominal Pain in a Young Man

Ibrahim Öz<sup>1\*</sup>, Ismail Şerifoğlu<sup>1</sup>, Yücel Üstündag<sup>2</sup> and Oge Tascilar<sup>3</sup>

<sup>1</sup>Department of Radiology, Bülent Ecevit University, Zonguldak, Turkey

<sup>2</sup>Department of Gastroenterology, Bülent Ecevit University, Zonguldak, Turkey

<sup>3</sup>Department of General Surgery, Bülent Ecevit University, Zonguldak, Turkey

## ARTICLE INFO

### Article history:

Received: 8 October 2013

Accepted: 7 May 2014

### Online:

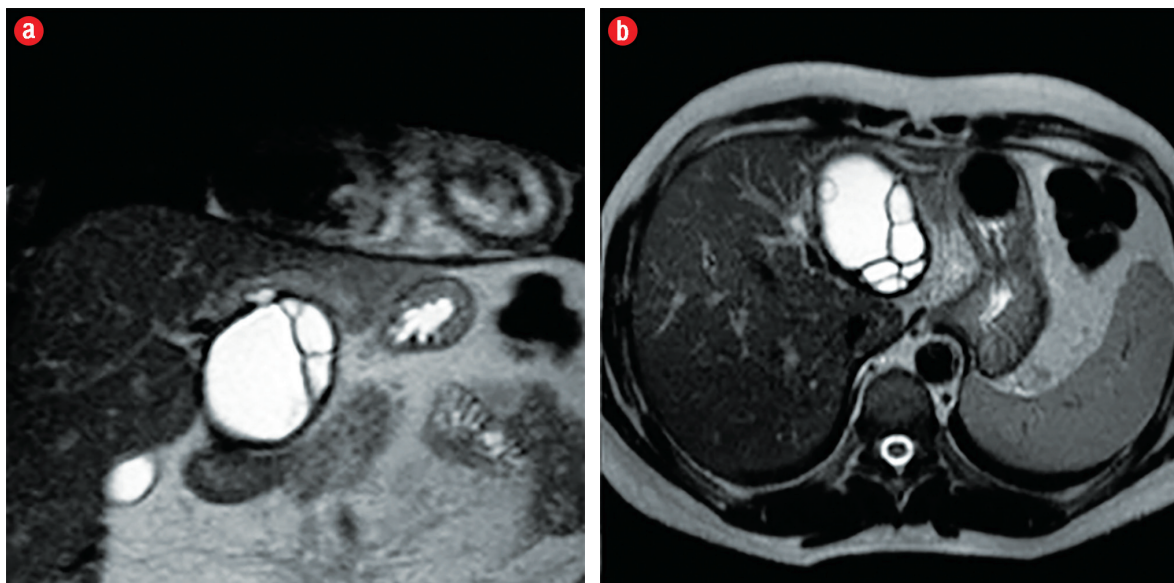
DOI 10.5001/omj.2015.31

**A** 29-year-old man presented to the gastroenterology department, Bülent Ecevit University Hospital, with one week history of continuous abdominal pain in the epigastric and right upper quadrant of the abdomen. The pain was unrelated to food consumption, and there was accompanying nausea but no vomiting. His past medical history was uneventful.

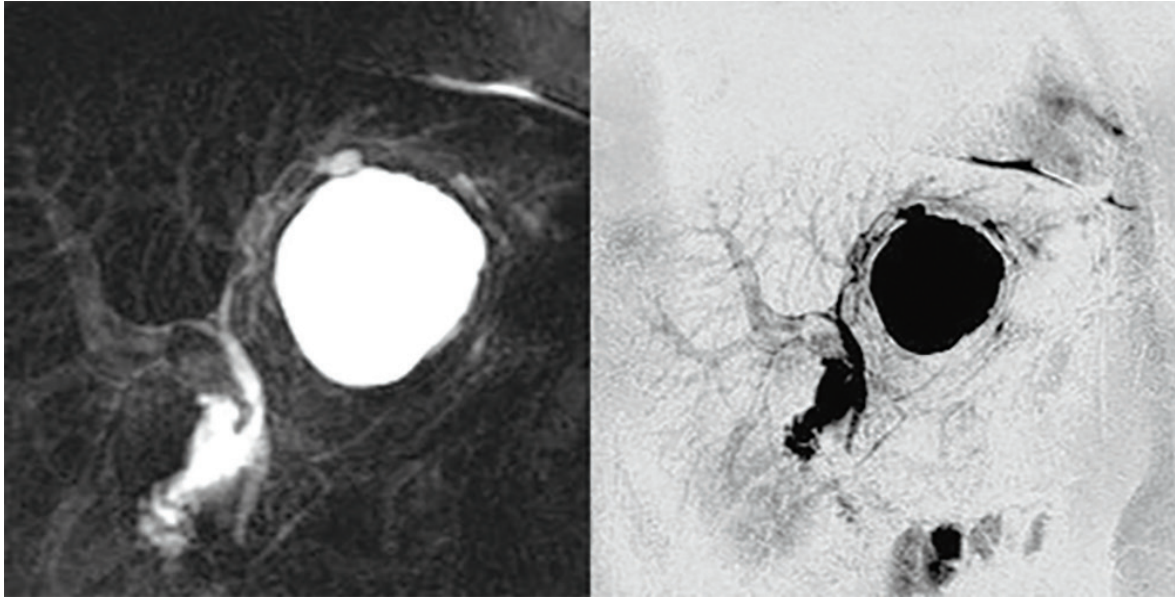
On physical examination, the patient was alert and oriented. His temperature was 36.7°C, he had a regular pulse which measured 78 beats/min, and his blood pressure was 120/70mmHg. There was epigastric tenderness on deep palpation. There was no guarding and no rebound tenderness.

His respiratory and cardiovascular system examinations were normal.

Laboratory investigations revealed: C-reactive protein 13.2mg/L (0–8mg/L normal), serum alanine transaminase 378U/L (10–49U/L normal), serum aspartate aminotransferase 405U/L (120–246U/L normal), serum gamma-glutamyl transpeptidase 591U/L (0–73U/L normal), serum lactate dehydrogenase 348U/L (120–246U/L normal), serum alkaline phosphatase 158IU (80–280IU normal), total bilirubin 2.0mg/dL (0.3–1.2mg/dL normal), amylase 32U/L (30–118U/L normal), and lipase 24U/L (6–51 U/L normal). The results of a complete blood count, electrolyte panel, and



**Figure 1:** Sagittal (a) and axial (b) T2-weighted magnetic resonance imaging revealed hyperintense cystic lesion with hypointense rim in the liver.



**Figure 2:** Magnetic resonance cholangiopancreatography revealed cystic lesion and biliary system.

renal function tests were normal. An abdominal ultrasonography showed a well-demarcated anechoic cystic lesion, 75mm in diameter with multiple septations in the left liver lobe. Magnetic resonance imaging and magnetic resonance cholangiopancreatography were also performed [Figure 1 and 2].

#### *Questions*

1. What is the diagnosis based on the imaging?
2. What are your treatment options?

*Answers to the quiz, and the full article, can be found online at [www.omjournal.org](http://www.omjournal.org).*